From bloodjournal.hematologylibrary.org by guest on May 27, 2012. For personal use only.

blood

2009 114: 4337-4353
Prepublished online August 20, 2009;
doi:10.1182/blood-2009-07-202895

How I treat mycosis fungoides and Sézary syndrome

H. Miles Prince, Sean Whittaker and Richard T. Hoppe

Updated information and services can be found at:
http://bloodjournal.hematologylibrary.org/content/114/20/4337.full.html

Articles on similar topics can be found in the following Blood collections
Free Research Articles (1415 articles)
How I Treat (87 articles)
Lymphoid Neoplasia (1112 articles)

Information about reproducing this article in parts or in its entirety may be found online at:
http://bloodjournal.hematologylibrary.org/site/misc/rights.xhtml#repub_requests

Information about ordering reprints may be found online at:
http://bloodjournal.hematologylibrary.org/site/misc/rights.xhtml#reprints

Information about subscriptions and ASH membership may be found online at:
http://bloodjournal.hematologylibrary.org/site/subscriptions/index.xhtml

Blood (print ISSN 0006-4971, online ISSN 1528-0020), is published weekly by the American Society of Hematology, 2021 L St, NW, Suite 900, Washington DC 20036.
Copyright 2011 by The American Society of Hematology; all rights reserved.

From bloodjournal.hematologylibrary.org by guest on May 27, 2012. For personal use only.

How I treat mycosis fungoides and Sézary syndrome

H. Miles Prince,[1] Sean Whittaker,[2] and Richard T. Hoppe[3]

[1]Division of Haematology and Medical Oncology, Peter MacCallum Cancer Centre and University of Melbourne, Victoria, Australia; [2]St John's Institute of Dermatology, Guy's and St Thomas' NHS Foundation Trust and Division of Genetics and Molecular Medicine, King's College London, London, United Kingdom; and [3]Department of Radiation Oncology, Stanford University, CA

The most common subtypes of primary cutaneous T-cell lymphomas are mycosis fungoides (MF) and Sézary syndrome (SS). The majority of patients have indolent disease; and given the incurable nature of MF/SS, management should focus on improving symptoms and cosmesis while limiting toxicity. Management of MF/SS should use a "stage-based" approach; treatment of early-stage disease (IA-IIA) typically involves skin directed therapies that include topical corticosteroids, phototherapy (psoralen plus ultraviolet A radiation or ultraviolet B radiation), topical chemotherapy, topical or systemic bexarotene, and radiotherapy. Systemic approaches are used for recalcitrant early-stage disease, advanced-stage disease (IIB-IV), and transformed disease and include retinoids, such as bexarotene, interferon-α, histone deacetylase inhibitors, the fusion toxin denileukin diftitox, systemic chemotherapy including transplantation, and extracorporeal photopheresis. Examples of drugs under active investigation include new histone deacetylase inhibitors, forodesine, monoclonal antibodies, proteasome inhibitors, and immunomodulatory agents, such as lenalidomide. It is appropriate to consider patients for novel agents within clinical trials if they have failed front-line therapy and before chemotherapy is used. (Blood. 2009;114:4337-4353)

Introduction

Primary cutaneous lymphomas are composed of both T-cell (75%+) and B-cell lymphomas and are rare conditions representing 2% of all lymphomas with an annual incidence of 0.3 to 1 per 100 000.[1,2] There are a variety of different types of cutaneous T-cell lymphoma (CTCL); and until relatively recently, there were 2 classifications for CTCL, the World Health Organization (WHO)[3] and the European Organization for Research and Treatment of Cancer (EORTC),[4] the latter characterized by dividing the entities into aggressive or indolent conditions based on clinicopathologic criteria. In 2005, the 2 classification systems were combined (Table 1). In this review, we focus on the most common forms of CTCL, mycosis fungoides (MF) and its leukemic variant, Sézary syndrome (SS).

The wide array of clinical presentations and possible treatment modalities makes the treatment of MF/SS complex, and there are no simple treatment algorithms. There are several published guidelines, which we recommend the reader review, that provide more detail around the rationale of our management approaches to the various presentations of MF/SS. These include the National Cancer Center Network guidelines (www.nccn.org)[5] and those by the European Society of Medical Oncology[6] and the EORTC,[7] with our approach most closely reflecting the latter. It is, however, very important to recognize that these guidelines are based on a somewhat restricted evidence base as CTCLs are very rare diseases with very few randomized trials performed to date. Moreover, when planning treatment, individual patient factors need to be considered, such as age and comorbidities, especially the risk of infection for which patients with MF/SS are particularly prone. The management approach is truly multidisciplinary; and, as such, we hope to provide the combined perspectives of a dermatologist, radiation oncologist, and hematologist-oncologist. A summary of the various treatment options we generally consider are outlined in Table 2 and, in this review, we aim to address the most common clinical scenarios the clinician faces.

Investigations

It cannot be overemphasized that the diagnosis of CTCL requires clinicopathologic correlation, and review by a pathologist colleague experienced in these disorders is strongly recommended. A consensus approach to diagnosis of early-stage MF has been recently reported by the International Society of Cutaneous Lymphoma (ISCL) with the majority of cases of CTCL diagnosed on hematoxylin-and-eosin sections with appropriate immunophenotyping, most commonly by immunohistochemistry and in some cases by flow cytometry and clonal T-cell receptor gene rearrangement by polymerase chain reaction on fresh and formalin-fixed tissue.[8] The approach to diagnosis is summarized in Table 3 and uses an algorithm integrating clinical and laboratory assessments.

It is also important to recognize that it is not uncommon for the diagnosis of MF to remain elusive for many years, often requiring observation and repeated biopsies.[9,10] Such an approach avoids embarking on numerous investigations in a disease that is generally indolent and where outcome is not altered by aggressive early intervention.

Non-MF cutaneous T-cell lymphoma

A key aspect of the management of CTCL is to distinguish the rare non-MF CTCL entities from MF.[1] Clinical presentation will often help distinguish them from MF, and clinicopathologic correlation is critical to distinguish MF from other rarer CTCL subtypes, transformed disease, peripheral T-cell lymphoma or perhaps even a

Submitted July 5, 2009; accepted August 5, 2009. Prepublished online as *Blood* First Edition paper, August 20, 2009; DOI 10.1182/blood-2009-07-202895.

© 2009 by The American Society of Hematology

From bloodjournal.hematologylibrary.org by guest on May 27, 2012. For personal use only.

Table 1. WHO-EORTC classification of cutaneous lymphomas with primary cutaneous manifestations[1]

Classification
Cutaneous T-cell and NK-cell lymphomas
MF
MF variants and subtypes
Folliculotropic MF
Pagetoid reticulosis
Granulomatous slack skin
Sézary syndrome
Adult T-cell leukemia/lymphoma
Primary cutaneous CD30$^+$ lymphoproliferative disorders
Primary cutaneous anaplastic large cell lymphoma
Lymphomatoid papulosis
Subcutaneous panniculitis-like T-cell lymphoma
Extranodal NK-/T-cell lymphoma, nasal type
Primary cutaneous peripheral T-cell lymphoma, unspecified
Primary cutaneous aggressive epidermotropic CD8$^+$ T-cell lymphoma (provisional)
Cutaneous γ/δ T-cell lymphoma (provisional)
Primary cutaneous CD4$^+$ small-/medium-sized pleomorphic T-cell lymphoma (provisional)
Cutaneous B-cell lymphomas
Primary cutaneous marginal zone B-cell lymphoma
Primary cutaneous follicle center lymphoma
Primary cutaneous diffuse large B-cell lymphoma, leg type
Primary cutaneous diffuse large B-cell lymphoma, other intravascular large B-cell lymphoma
Precursor hematologic neoplasm
CD4$^+$/CD56$^+$ hematodermic neoplasm (blastic NK-cell lymphoma)

rare variant of MF. The approach to management of non-MF CTCL is highly variable ranging from a conservative approach with CD30$^+$ CTCL, such as lymphomatoid papulosis (LyP), to a very aggressive approach in such conditions as cutaneous γ/δ T-cell lymphoma or primary cutaneous aggressive epidermotropic CD8$^+$ cytotoxic T-cell lymphoma. It is beyond the scope of this review to discuss the non-MF CTCL entities in detail, and we refer the reader to the WHO-EORTC manuscript for an overview of the clinical presentation and treatment strategies.[1]

Stage

The management of MF/SS is centered on a "stage-based" approach, and MF is classified into 4 clinical stages based on the TNM classification (Table 4), which then is synthesized into a clinically based staging system broadly divided into early- and advanced-stage disease[11] (Table 5). Skin patches and plaques occur in stage I, which is divided into IA ($<$ 10% body surface area [BSA]) or IB ($\geq$ 10% BSA). The presence of clinically evident lymphadenopathy without pathologic nodal infiltration represents stage IIA, cutaneous tumors characterize stage IIB, generalized erythroderma characterizes stage III, and pathologically positive lymph nodes (IVA) and visceral disease characterizing stage IVB. Patients with staged IA, IB, and IIA disease are considered to have "limited-stage" disease, and those with stages IIB (tumor), III (erythroderma), and IV (pathologic nodes with or without viscera) have "advanced-stage" disease.

Prognosis

Although MF/SS are generally considered incurable conditions, it is important to recognize that the majority of patients have an

Table 2. Summary of treatment options for MF/SS

Therapy	MF: Early-stage disease	MF: Advanced-stage disease	Sézary syndrome/ erythrodermic MF	Comments
Topical corticosteroids	++++	++	+++	Symptomatic control
PUVA	++++	+	+++	Availability may be restricted in nonmetropolitan areas
UVB	+++	+	++	More readily accessible than PUVA
Topical chemotherapy	+			If limited number of lesions
Imiquimod	+			If small lesions and limited number of lesions
Photodynamic therapy	+			If limited number of lesions; limited availability
Retinoids	+	+	+	Usually second line; less used since bexarotene became available
Bexarotene	++	+++	+++	Usually second line; can be used in combination with PUVA or IFN-α
Interferon-α	++	+++	++++	Second line
HDACi	+	+++	++++	Beyond second line
Oral MTX	+	+++	++	Low dose weekly
Localized radiotherapy	+	+++		If localized or large/plaques and tumor nodules
TSEB	+	++	+	For widespread disease
Systemic chemotherapy		++	++	Beyond second line
ECP		++++		If circulating clone detectable
Autologous transplantation		+	+	Very selected cases
Allogeneic transplantation		+	+	Very selected cases
Denileukin diftitox		++	++	Beyond second line
Alemtuzamab		+	+	Beyond second line; immunosuppressive
Proteasome inhibitors		+		Under investigation
Immunomodulatory agents (lenalidomide)		+		Under investigation

MF indicates mycosis fungoides; SS, Sézary syndrome; PUVA, psoralan ultraviolet A; UVB, ultraviolet B; ECP, extracorporeal photopheresis; HDACi, histone deacetylase inhibitors; and TSEB, total skin electron beam.

Crosses indicate frequency of use: ++++, almost always; +++, very frequently; ++, moderately frequently; and +, occasionally.

From bloodjournal.hematologylibrary.org by guest on May 27, 2012. For personal use only.

Table 3. Algorithm of diagnosing early MF developed by the ISCL[8]

	Criteria			Scoring system	
	Basic	Additional	Other	2 points	1 point
Clinical	Persistent and/or progressive patches/thin plaques	(1) Non–sun-exposed location (2) Size/shape variation (3) Poikiloderma		2 points for basic criteria and 2 additional criteria	1 point for basic criteria and 1 additional criteria
Histopathologic	Superficial lymphoid infiltrate	(1) Epidermotropism without spongiosis (2) Lymphoid atypia*		2 points for basic criteria and 2 additional criteria	1 point for basic criteria and 1 additional criteria
Molecular biologic			Clonal T-cell receptor gene rearrangement		1 point for clonality
Immunopathologic			$<$ 50% $CD2^+$, $CD3^+$, and/or $CD5^+$ cells $<$ 10% $CD7^+$ cells Epidermal/dermal discordance of CD2, CD3, CD5, or CD7†		1 point for 1 or more criteria

A total of 4 points is required for the diagnosis of MF based on any combination of points from the clinical, histopathologic, molecular biologic, and immunopathologic criteria.

*Lymphoid atypical is defined as cells with enlarged hyperchromatic nuclei and irregular or cerebriform nuclear contours.

†T-cell antigen deficiency confined to the epidermis.

Table 4. ISCL/EORTC revision to the classification of MF and SS[11]

TNMB classification	Characteristics
Skin	
T1	Limited patches,* papules, and/or plaques† covering $<$ 10% of the skin surface; may further stratify into T1a (patch only) versus T1b (plaque $\pm$ patch)
T2	Patches, papules, or plaques covering $\geq$ 10% of the skin surface; may further stratify into T2a (patch only) versus T2b (plaque $\pm$ patch)
T3	One or more tumors‡ ($\geq$ 1 cm diameter)
T4	Confluence of erythema covering $\geq$ 80% BSA
Node	
N0	No clinically abnormal peripheral lymph nodes§; biopsy not required
N1	Clinically abnormal peripheral lymph nodes; histopathology Dutch grade 1 or NCI LN0-2
N1a	Clone negative‖
N1b	Clone positive‖
N2	Clinically abnormal peripheral lymph nodes; histopathology Dutch grade 2 or NCI LN3
N2a	Clone negative‖
N2b	Clone positive‖
N3	Clinically abnormal peripheral lymph nodes; histopathology Dutch grades 3-4 or NCI LN4; clone positive or negative
Nx	Clinically abnormal peripheral lymph nodes; no histologic confirmation
Visceral	
M0	No visceral organ involvement
M1	Visceral involvement (must have pathology confirmation¶ and organ involved should be specified)
Blood	
B0	Absence of significant blood involvement: $\leq$ 5% of peripheral blood lymphocytes are atypical (Sézary) cells#
B0a	Clone negative‖
B0b	Clone positive‖
B1	Low blood tumor burden: $>$ 5% of peripheral blood lymphocytes are atypical (Sézary) cells but does not meet the criteria of B_2
B1a	Clone negative‖
B1b	Clone positive‖
B2	High blood tumor burden: $\geq$ 1000/μL Sézary cells# with positive clone‖

*For skin, patch indicates any size skin lesion without significant elevation or induration. Presence/absence of hypopigmentation or hyperpigmentation, scale, crusting, and/or poikiloderma should be noted.

†For skin, plaque indicates any size skin lesion that is elevated or indurated. Presence or absence of scale, crusting, and/or poikiloderma should be noted. Histologic features, such as folliculotropism or large-cell transformation ($>$ 25% large cells), $CD30^+$ or $CD30^-$, and clinical features, such as ulceration, are important to document.

‡For skin, tumor indicates at least one 1-cm diameter solid or nodular lesion with evidence of depth and/or vertical growth. Note total number of lesions, total volume of lesions, largest size lesion, and region of body involved. Also note if histologic evidence of large-cell transformation has occurred. Phenotyping for CD30 is encouraged.

§For node, abnormal peripheral lymph node(s) indicates any palpable peripheral node that on physical examination is firm, irregular, clustered, fixed, or 1.5 cm or larger in diameter. Node groups examined on physical examination include cervical, supraclavicular, epitrochlear, axillary, and inguinal. Central nodes, which are not generally amenable to pathologic assessment, are not currently considered in the nodal classification unless used to establish N3 histopathologically.

‖A T-cell clone is defined by polymerase chain reaction or Southern blot analysis of the T-cell receptor gene.

¶For viscera, spleen and liver may be diagnosed by imaging criteria.

#For blood, SCs are defined as lymphocytes with hyperconvoluted cerebriform nuclei. If SCs are not able to be used to determine tumor burden for B2, then one of the following modified ISCL criteria along with a positive clonal rearrangement of the TCR may be used instead: (1) expanded $CD4^+$ or $CD3^+$ cells with CD4/CD8 ratio of 10 or more; or (2) expanded $CD4^+$ cells with abnormal immunophenotype including loss of CD7 or CD26.

From bloodjournal.hematologylibrary.org by guest on May 27, 2012. For personal use only.

Table 5. ISCL/EORTC revision to the staging of mycosis fungoides and Sézary syndrome

	T	N	M	B
IA	1	0	0	0, 1
IB	2	0	0	0, 1
IIA	1, 2	1, 2	0	0, 1
Advanced-stage disease[11]				
IIB	3	0-2	0	0, 1
III	4	0-2	0	0, 1
IIIA	4	0-2	0	0
IIIB	4	0-2	0	1
IVA_1	1-4	0-2	0	2
IVA_2	1-4	3	0	0-2
IVB	1-4	0-3	1	0-2

indolent form of the disease and will live for many years. Indeed, it is estimated that 65% to 85% of patients with MF have stage IA or IB disease.[9,12] The most important factor in planning management and determining prognosis is the stage of the disease. Indeed, the majority of patients with early-stage disease (stages IA, IB, and IIA) do not progress to more advanced-stage disease, and patients presenting with isolated patch or plaque disease (T1-T2) have a median survival of more than 12 years[12-14] (Figure 1). Moreover, patients with stage IA disease do not appear to have a decreased survival compared with an age-, sex-, and race-matched population.[13]

Patients with advanced-stage disease (stages IIB, III, and IVA) with tumors, erythroderma, and lymph node or blood involvement but no visceral involvement have a median survival of 5 years from time of presentation. Of note, patients with tumors (T3) have an inferior outcome to those with erythroderma (T4). Patients with visceral involvement are rare (stage IVB) and have a median survival of only 2.5 years or less.[9,12,13,15,16]

Investigations. The approach to staging the patient is summarized in Table 6 and based on the recommendations of the ISCL.[11] For patients with clinically very limited-stage disease with skin patches and/or plaques with no palpable lymphadenopathy, extensive staging investigations are not generally required. Occasional patients will present with locoregional lymphadenopathy, which may reflect dermatopathic changes in the node rather than true nodal involvement with MF. Thus, it is not always necessary to biopsy every patient with mildly enlarged nodes. In general, we recommend biopsy of nodes larger than 1.5 cm as nodal involvement has substantial prognostic impact (Table 4). The relative hesitancy in performing node biopsies relates to the high incidence of skin colonization with pathogenic organisms in patients with MF/SS, which increases the risk of infection after surgery.

Prognostic characteristics beyond stage. Clinical stage is by far the most important predictor of outcome. However, within early-stage MF, there is some prognostic heterogeneity. Indeed, we recognize an "intermediate-risk" group between early- and advanced-stage disease. This includes patients with stage IIA/IB folliculotropic variant of MF and patients with very thick plaques.[17,18] The relatively inferior outcomes in these groups are thought to be the result of its reduced responsiveness to skin-directed therapy (SDT).[19] For advanced-stage disease, patients with stage IIB disease with multiple tumor nodules (a higher tumor burden) and large-cell transformation of MF have a substantially poorer prognosis (see "Transformed disease").[9] Low numbers of $CD8^+$ T cells in the dermal infiltrate and/or the blood have also been independently associated with reduced survival.[14,20,21]

Managing early-stage (IA-IIA) MF

Overview

As mentioned, the majority of patients present with early-stage disease (Table 7). As the use of early application of therapy does not impact on survival,[16] a nonaggressive approach to therapy is warranted with treatment aimed at improving symptoms and cosmesis while limiting toxicity. As patients with stage IA disease have a long life expectancy, an "Expectant Policy" may be a legitimate management option in selected patients, provided that it incorporates careful monitoring. Given that multiple skin sites are often involved, the initial treatment is primarily SDT, which aims to control skin lesions while minimizing morbidity. The key choices for SDT are topical or intralesional corticosteroids or psoralen plus ultraviolet A radiation (PUVA) or ultraviolet B (UVB). Indeed, for patients with limited patch disease, topical steroids often control the disease for many years, and often this is the only form of therapy required for such patients. Patch and thin plaque MF can be treated with topical corticosteroids. Class I (potent) topical corticosteroids, such as betamethasone dipropionate 0.05% or mometasone furoate 0.1%, are the most effective at obtaining objective disease regression. Patients with stage T1 disease have an approximately 60% to 65% complete response (CR) rate and a 30% partial response (PR) rate with topical steroids. Patients with T2 disease (generalized patch/plaque with > 10% of skin surface involved) have a 25% CR rate and a 57% PR rate. Topical corticosteroids have CR rates similar to other forms of SDTs.[22] Intralesional corticosteroids can be effective in treating thicker MF lesions, such as plaques or tumor deposits.

For more widespread disease, phototherapy with PUVA or UVB is recommended. Response rates to PUVA therapy in patients with patch disease are high with CR rates of approximately 58% to 83% and overall response rates of up to 95%.[23,24] Furthermore, remission is often prolonged with a reported mean duration of 43 months.[23] Maintenance treatment with weekly or fortnightly therapy can be effective in maintaining remission. PUVA therapy is generally well tolerated; however, acute side effects include nausea (from the oral psoralens) or photosensitivity. Long-term side effects are acceleration of actinic damage and an increased rate of skin malignancies, including squamous cell carcinoma and melanoma.[25-27]

UVB is also effective for MF, especially for patch and thin plaque disease. Broadband UVB (300-320 nm) was initially used,

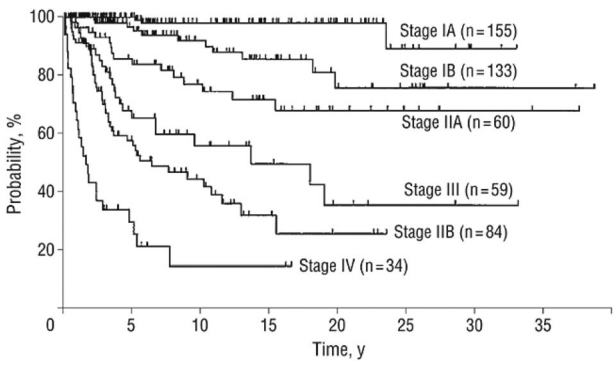

Figure 1. Actuarial disease-specific survival of 525 patients with MF and SS according to their clinical stage at diagnosis (stages IA-IV).[12] For stage IA versus IB disease, $P = .007$; for stage IB versus IIA disease, $P = .006$; for stage IIA versus IIB disease, $P < .001$; for stage IIA versus III disease, $P = .03$; for stage IIB versus III disease, $P = .09$; and for stage IA-III versus IV disease, $P < .001$.

From bloodjournal.hematologylibrary.org by guest on May 27, 2012. For personal use only.

and more recently narrow band UVB (311 nm) has also been shown to be effective in MF, although remission duration with the latter may be inferior. The advantage of UVB over PUVA is that it is more readily available (more community-based dermatology practices have UVB equipment) and avoids the need for protective sunglasses and the side effects, albeit modest, of psoralen. The disadvantage of UVB is its somewhat lower response rate and duration of remission and less effective than PUVA with thicker lesions.[28,29] PUVA has been reported to achieve improved response rates when combined with interferon-α-2b (IFN-α)[30,31] or retinoids such as acitretin.[32] PUVA therapy has also been used as a salvage or maintenance therapy after total skin electron beam (TSEB) therapy.[33] For even thicker plaques, particularly if localized, radiotherapy is effective as the disease is highly radiosensitive (see "Radiotherapy").

Other choices for first-line therapy are topical chemotherapy using mechlorethamine (nitrogen mustard [NM]) or carmustine. However, the use of these agents can be impractical if lesions are extensive and, with long-term use, carry a risk of secondary epidermal cancer. Moreover, particular care must be taken to avoid topical exposure to those carers assisting with the application of the solution or ointment. Drug hypersensitivity is reported to occur in up to 45% or more of patients treated with topical NM, particularly in solution form. NM ointment reduces the incidence of allergic reactions; however, it involves considerable pharmacy preparation and consequently is not readily available. Skin sensitivity occurs in up to 5% of patients treated with carmustine. Other localized therapies include imiquimod[34] and photodynamic therapy,[24] but the latter is limited to specialized centers.

"Second-line" therapy for early-stage disease is often retinoids or rexinoids (bexarotene), IFN-α, low-dose oral methotrexate (MTX), histone deacetylase inhibitors (HDACi), or denileukin diftiox. Such second-line therapy can be highly effective for disease refractory to topical therapies, and these choices are always considered before the use of chemotherapy. Radiotherapy is a highly effective therapy in MF/SS and can be used for both early- and advanced-stage disease, as first-line or relapsed/progressive disease.

Radiotherapy

Cutaneous lymphomas are usually highly radiosensitive, and radiation therapy may play a major role in the management of many patients with MF.[35] Partial regression of disease may be observed with single doses as low as 1.0 Gy.[36] However, permanent eradication of all disease using radiotherapy alone is an elusive goal. Thus, treatment is usually aimed at improving symptoms and cosmesis. Nonetheless, there is the very occasional patient who presents with truly localized MF (single lesion) often around the "bathing trunk" distribution or breast. Whether this is curable is unknown, but our approach is similar to the management of other low-grade lymphomas: to treat such patients with local radiotherapy with "curative" intent to a dose of approximately 30 Gy. A large proportion of these patients may remain disease-free.[37]

The likelihood of achieving a CR and the durability of those responses decreases with increasing stage of disease; patients with T1 disease have a more than 80% CR rate with radiotherapy (either local field or TSEB therapy), compared with 20% to 30% CR rates for T4 disease. Five-year relapse-free survival rates with radiation alone are 40% to 60% for T1 disease, but less than 10% for T4 disease.[37] Irrespective of stage and curability, however, radiotherapy can provide excellent palliation of troublesome symptoms of MF/SS, such as pruritus, scaling, and ulceration.

Target volume. For most patients, the target volume is the epidermis and/or dermis, that is, the maximum depth of interest is only a few millimeters from the skin surface unless there are tumors or deep ulcers. Most lesions may therefore be treated with

Table 6. Recommended evaluation/initial staging of the patient with mycosis fungoides/Sézary syndrome[11]

Evaluation and staging
Complete physical examination, including:
Determination of type(s) of skin lesions
If only patch/plaque disease or erythroderma, then estimate percentage of BSA involved and note any ulceration of lesions
If tumors are present, determine total number of lesions, aggregate volume, largest size lesion, and regions of the body involved
Identification of any palpable lymph node, especially those ≥ 1.5 cm in largest diameter or firm, irregular, clustered, or fixed
Identification of any organomegaly
Skin biopsy
Most indurated area if only one biopsy
Immunophenotyping to include at least the following markers: CD2, CD3, CD4, CD5, CD7, and CD8, and a B-cell marker, such as CD20; CD30 may also be indicated in cases where lymphomatoid papulosis, anaplastic lymphoma, or large-cell transformation is considered
Evaluation for clonality of TCR gene rearrangement
Blood tests
CBC with manual differential, liver function tests, LDH, comprehensive chemistries
TCR gene rearrangement and relatedness to any clone in skin
Analysis for abnormal lymphocytes by either SC count with determination absolute number of SCs and/or flow cytometry (including $CD4^+/CD7^-$ or $CD4^+/CD26^-$)
Radiologic tests
In patients with $T_1N_0B_0$ stage disease who are otherwise healthy and without complaints directed to a specific organ system; and in selected patients with $T_2N_0B_0$ disease with limited skin involvement, radiologic studies may be limited to a chest x-ray or ultrasound of the peripheral nodal groups to corroborate the absence of adenopathy
In all patients with other than presumed stage IA disease, or selected patients with limited T_2 disease and the absence of adenopathy or blood involvement, CT scans of chest, abdomen, and pelvis alone ± FDG-PET scan are recommended to further evaluate any potential lymphadenopathy, visceral involvement, or abnormal laboratory tests; in patients unable to safely undergo CT scans, MRI may be substituted.
Lymph node biopsy
Excisional biopsy is indicated in those patients with a node that is either ≥ 1.5 cm in diameter and/or is firm, irregular, clustered, or fixed
Site of biopsy: preference is given to the largest lymph node draining an involved area of the skin or if FDG-PET scan data are available, the node with highest standardized uptake value; if there is no additional imaging information and multiple nodes are enlarged and otherwise equal in size or consistency, the order of preference is cervical, axillary, and inguinal areas
Analysis: pathologic assessment by light microscopy, flow cytometry, and TCR gene rearrangement

TCR indicates T-cell receptor; CBC, complete blood count; and FDG-PET, ^{18}F-fluoro-2-deoxyglucose positron emission tomography.

From bloodjournal.hematologylibrary.org by guest on May 27, 2012. For personal use only.

very soft (low penetrance) beams: superficial x-ray therapy (50-145 kvp) or 4 to 9 MeV electron beams. Higher-energy beams (orthovoltage/megavoltage) are occasionally necessary for thicker lesions.

TSEB therapy is usually reserved for patients with extensive skin involvement and can be used as first- or second-line therapy for patients with extensive T2 or T3 disease, occasional patients with T4 disease, and those who are no longer responding to topical therapies. Even when the responses are incomplete or the duration of complete response is brief, patients usually achieve significant clinical benefit. It is a complex technique and requires the use of either multiple field arrangements or a rotational technique, with "patching" or "boosting" for areas of underdosing and self-shielding (eg, soles of feet, perineum) and takes 6 to 10 weeks to complete.

Dose. A wide range of radiation doses may be used in the management of these patients. For symptomatic treatment of individual lesions, the dose may even be titrated to the response and usually 15 to 20 Gy is sufficient. Although very small doses of radiation can provide effective palliation of these lesions, there does appear to be a dose-response relationship for complete remission, especially in the context of TSEB therapy. Doses of 10 to 20 Gy are associated with a CR rate of only 55%, whereas doses of 30 Gy or greater are associated with a 94% CR rate. In addition, the durability of responses is greater for patients treated with higher doses.[38] The maximum dose that is tolerated in a single course of TSEB is approximately 36 Gy, beyond which there is significant acute toxicity.

Combined modality treatments. For patients with extensive and/or resistant disease, radiation has been used sequentially with several other treatments: PUVA, UVB, retinoids, and topical or systemic chemotherapy. Occasionally, treatments may be administered concurrently, but doses of radiation will have to be modified if large fields are being treated to minimize the risk for erythema or desquamation. Extreme modifications to the radiation schedule and lengthy treatment breaks may compromise the effectiveness of the radiotherapy. TSEB followed by adjuvant PUVA, NM, photopheresis, or other adjuvants does lead to a significant benefit in disease-free survival, but not in overall survival (OS).[39,40] One combined modality approach for patients with extensive disease that we have found to have promising efficacy is the use of 2 or 3 courses of chemotherapy, eg, high-dose MTX (> 1 g/m^2) or liposomal doxorubicin to reduce disease to clinically minimal levels before proceeding with TSEB.

Patient factors. Many patients with MF/SS are in good general health and may be working full-time. Others may be elderly or not reside close to a center that offers TSEB therapy. In either case, a 10-week course of treatment may not be feasible and other management options will have to take precedence. Coexisting medical problems rarely preclude a patient from radiotherapy, but there are some contraindications, eg, scleroderma, or inability to stand for several minutes at a time during TSEB therapy.

Table 7. Recommendations for treatment of MF stages IA, IB, and IIA

Treatment	Comments*
First-line	
"Expectant policy"	Usually suitable for those with stage IA disease in conjunction with symptomatic treatment if required; patients with single lesion may be considered for "curative therapy" with radiation therapy
PUVA	For patch/plaque disease; requires regular 2 or 3 times/week treatment; there may be limited availability of PUVA in nonmetropolitan areas; can be combined with retinoids/rexinoids
UVB	For patch stage disease as skin penetration not as deep as PUVA; requires regular 2 or 3 times/week treatment and generally more readily available than PUVA
Topical corticosteroids	Simple therapy; toxicities if extensive skin application for long periods
Topical bexarotene	For limited sites of disease; simple therapy; local reactions may occur
Topical NM	For limited sites of disease or generalized involvement; local reactions occasionally problematic; ointment causes fewer reactions; availability of NM worldwide has been a problem recently
Topical carmustine	Rarely used now; for limited sites of disease; local reactions may occur; causes telangiectasias
Localized radiotherapy	Especially for patients with limited number of lesions and/or thickened plaques; durable remissions achieved
TSEB	Patients with stage IB disease with relatively slow progression; limited availability; can take 6 to 10 weeks to complete
Second-line+	
Oral bexarotene	Generally well tolerated and convenient (oral capsule); some responses can be very durable; most common side effects are hypertriglyceridemia and hypothyroidism that usually require treatment; other relatively common side effects are rash and headache; can be used in conjunction with other therapies
IFN-α monotherapy	Major difficulty is tolerance and compliance; some responses can be very durable; somewhat inconvenient (daily subcutaneous injection); most common side effect is fatigue, particularly in older patients; requires moderately high doses aiming for 3 to 5+ MU/day; monitor FBC and thyroid function; IFN-α can also be combined with PUVA, retinoids, bexarotene
Low-dose MTX	Generally well tolerated and convenient (oral weekly); dose-response effect is common and usually starts at 20 to 30 mg/week (up to 60-70 mg/week); some responses can be very durable; most common side effects are cytopenias and long-term risk of liver disease; very effective in patients with coexistent lymphomatoid papulosis; can be used in conjunction with other therapies, such as steroids, ECP, PUVA, IFN-α
Vorinostat	Only approved HDACi currently; generally well tolerated and convenient (oral daily); there appears to be a dose-response effect in some patients; most common SEs are fatigue, lethargy, mild/moderate thrombocytopenia and elevated creatinine and taste changes; can improve itch even when skin lesions remain; some responses can be very durable; virtually no data on use in combination with other therapies, such as PUVA, IFN-α, MTX, chemotherapy
Denileukin diftitox	Generally considered after trial of bexarotene and/or HDACi; inconvenient administration requiring daily dosing times 5 days every 3 weeks (6-8 courses); patient's tumor must express CD25 (although responses are observed in patients with CD25$^-$ lesions); there can be substantial supportive care requirements for some patients during therapy who develop capillary leak syndrome; some responses can be very durable even in heavily pretreated patients
Novel agents within clinical trials	In patients with stage IA-IIA disease, chemotherapy is not recommended and novel agents within clinical trials are generally recommended before chemotherapy is considered (see Table 12)

*For more details and detailed references, we refer the reader to the EORTC consensus recommendations for the treatment of mycosis fungoides/Sézary syndrome.[7]

From bloodjournal.hematologylibrary.org by guest on May 27, 2012. For personal use only.

Retinoids and rexinoids

Retinoids belong to the family of steroid hormones, which bind to the nuclear receptors (retinoic acid receptor [RAR]; retinoid X receptor [RXR]) and subsequently interact with various transcription factors. RAR and RXR have various isoforms (α, β, and γ), which are differentially expressed in tissues. The skin contains both RAR and RXR. Non–RXR-selective retinoids, such as oral etretinate, arotinoid, acitretin, and isotretinoin (13-*cis*-retinoic acid), have been used alone or in combination with PUVA, IFN-α, or even chemotherapy and are reported to have response rates in the range of 5% to 65%.[31,32,41-45] Bexarotene is a new synthetic rexinoid that selectively binds to the RXR subfamily and is formulated as either as capsule or a topically applied gel.[46,47] In our experience, oral bexarotene can achieve responses in chemoradiotherapy refractory patients within 2 to 4 months, and those patients may have a sustained benefit provided that the RXR-induced hyperlipidemia is manageable, allowing an optimal therapeutic dose. Bexarotene may also be useful in maintaining responses after SDT.[46,48-50] Topical bexarotene is particularly useful for patients who have a limited number of patches or plaques, and we recommend its use before topical chemotherapy.[47] In general terms, bexarotene is being used more frequently in MF/SS, often in place of the earlier generation retinoids.

IFN-α and related biologic response modifiers

IFN-α, a biologic response modifier, should generally be considered as second-line therapy for stage IA-IB disease and a first-line therapy for IIB, III, and SS and is effective at moderately high doses of 3 million to 10 million units (MU) daily or 3 times/week.[51-53] Time to response is in the order of weeks, and it can be combined with PUVA, chemotherapy, retinoids, and bexarotene.[30,31,41,42,46,50,54,55] In advanced-stage disease, our preference is to use single-agent IFN-α first, adding PUVA if there is more widespread pruritus and adding bexarotene if the response is suboptimal. Prolonged responses have also been observed with γ-interferon.[56] Recombinant interleukin-12 (IL-12) has efficacy in MF, but limited availability does not make it a realistic treatment option at present.[57]

Low-dose MTX

There are few published reports on the use of MTX in MF,[58,59] with the largest series of 60 patients with patch/plaque MF (T2) achieving a 12% CR and 22% PR rate with a median time to treatment failure of 15 months.[58] In this study, the median weekly dose was 25 mg with maximum doses up to 75 mg. Low-dose MTX has been successfully combined with IFN-α.[60]

Clinical case 1: early-stage disease and SDT

Scenario

A 42-year-old woman living in large metropolitan city presented with stage IB MF with predominantly cutaneous patches on the trunk involving 40% of the BSA (Figure 2).

Figure 2. Patient with stage IB disease with patches and thin plaques.

Management

The patient commenced PUVA therapy 3 times/week for 6 months with complete resolution of lesions. PUVA was continued for a further 3 months, twice a week and then discontinued. Localized lesions returned (~ 5% of BSA) on her trunk 40 months later. By that time, the patient had moved 140 miles from the city. PUVA was not used because of inconvenience and a limited extent of cutaneous disease. Topical corticosteroids were used initially with good response for 3 years. When more extensive lesions with plaques developed, the patient was treated successfully with IFN-α 3 MU daily with complete resolution of symptoms. At the time of next progression, we will consider retreatment with PUVA (if convenient) with or without oral bexarotene or IFN-α.

Comment

This case highlights the durable effect of SDT and how therapy options need to be individualized.

Clinical case 2: early-stage disease and SDT for "intermediate-prognosis" disease

Scenario

A 65-year-old patient presented with multiple patches and plaques (> 50% of BSA), some showing clinical and histologic evidence of

From bloodjournal.hematologylibrary.org by guest on May 27, 2012. For personal use only.

Figure 3. Patient with stage IB disease with folliculotropic plaques on the trunk.

folliculotropism. Peripheral nodes in the inguinal and axillary areas were palpable with CT scan confirming that the largest axillary node measured 2.5 cm. A nodal biopsy revealed dermatopathic features confirming stage IIA disease (Figure 3).

Management

The patient was treated with PUVA phototherapy twice weekly for 4 months with only a limited partial clinical response. IFN-α was started (initially 3 MU 3 times/week, increasing to 6 MU 3 times/week) while the patient continued PUVA for a further 3 months. Prominent thick plaques involving facial areas and the inner thighs were treated with local superficial radiotherapy with complete resolution. The patient's disease responded with a good PR and resolution of peripheral lymphadenopathy after a further 3 months of therapy. Further superficial radiotherapy was used successfully to treat residual disease in the inguinal areas (shielded from PUVA). PUVA was discontinued after further maintenance weekly therapy for 2 months (cumulative UVA dose [550 J/cm^2]). Unfortunately, despite continuing IFN-α (3 MU 3 times per week) as maintenance therapy, the patient's disease relapsed within 4 months. Therefore, PUVA was restarted with bexarotene; but after a further 6 months of therapy, only a PR was achieved. Higher doses of bexarotene were not tolerated, and the cumulative dose of PUVA ($>$ 850 J/cm^2) was considered a relative contraindication to maintenance PUVA therapy in view of the known carcinogenic potential with high cumulative doses ($>$ 1200 J/cm^2). Therefore, the patient was treated with TSEB with a sustained complete remission.

Comment

This case illustrates what we could consider an intermediate prognostic disease in a patient with folliculotropic disease and dermatopathic nodal disease. Patients who are partially resistant to SDT often do well with combined modality treatment, especially PUVA plus IFN-α/bexarotene combinations with additional use of local skin radiotherapy for resistant plaques. The response duration to TSEB will be critical as extensive subsequent relapse, even with early cutaneous stages of disease, will represent a difficult management issue.

Advanced-stage (IIB-IVB) MF

Overview

Treatment of advanced-stage disease, or indeed refractory early-stage disease, is more problematic and always requires a multidisciplinary approach. Although systemic multiagent chemotherapy is often considered in patients with advanced-stage disease, the randomized National Cancer Institute study demonstrated that combination chemoradiotherapy offered no survival benefit over "conservative" sequential therapy.[16] Moreover, relatively rapid relapses are observed after chemotherapy; consequently, SDT or biologic response-modifying agents should be used first where practicable and systemic chemotherapy considered in patients progressing after these treatments. Critically, these patients will often have resistant or relapsed disease characterized by only cutaneous patches and plaques, which will require SDT rather than a traditional escalation of systemic therapy. The choice of systemic therapy depends largely on age, performance status of patient, tempo of the disease, risks of myelosuppression, and most importantly, stage. Thus, our approach is to separately consider treatment options of patients with stage IIB (Table 8), stage III/SS (Table 9), stage IV (Table 10), and transformed disease. In general, IFN-α, bexarotene, vorinostat, and the fusion toxin denileukin diftitox are generally considered before embarking on systemic chemotherapy. Conversely, for the relatively rare patient with stage IVB disease of suitable performance status, aggressive chemotherapy, including transplantation strategies, should be considered early. Novel agents within clinical trials should always be considered in these patients. The single-agent or multiagent chemotherapy regimens described in Table 11 are selected depending on disease characteristics and side-effect profile of the agents. The value of extracorporeal photopheresis (ECP) is generally limited to patients with erythrodermic disease and circulating malignant cells (see "SS").

Denileukin diftitox

Denileukin diftitox is a recombinant targeted fusion protein that combines the receptor-binding sequence of IL-2 with the cytotoxic A-chain and translocation B-chain of diphtheria toxin (DAB_{389}IL-2).[69-71] This drug has recently been approved by the Food and Drug Administration in the United States for patients with relapsed CTCL whose tumors express the IL-2 receptor subunit (CD25). This approval is based on superior outcomes in the first placebo-controlled randomized trial of systemic therapy in MF/SS.[72] The response rate was 49.1% at the 18 μg/kg dose with no statistically significant difference in RR in patients with early- or advanced-stage disease. Moreover, some patients had prolonged remissions with the median progression-free survival beyond 971 days in the 18 μg/kg arm. This benefit needs to be balanced against a toxicity profile that includes capillary leak

From bloodjournal.hematologylibrary.org by guest on May 27, 2012. For personal use only.

Table 8. Recommendations for treatment of MF stage IIB

Treatment	Comments*
First-line	
IFN-α	Can be effective even in patients with tumor and/or ulcerated lesions; see Table 7 for other comments; IFN-α can also be combined with PUVA, retinoids, bexarotene, MTX
TSEB and superficial X-irradiation	"Boosts" needed to site of thickened plaques/tumors; limited availability; can take 6 to 10 weeks to complete
PUVA	For patch/plaque disease; requires regular 2 or 3 times/week treatment; there may be limited availability of PUVA in nonmetropolitan areas; can be combined with retinoids/rexinoids, bexarotene, IFN-α
Second-line	
Bexarotene	See Table 7 for comments
Vorinostat	See Table 7 for comments
Denileukin diftitox	See Table 7 for comments
Novel agents within clinical trials	In patients with stage IIB disease, chemotherapy is recommended after bexarotene and/or and HDACi and/or DD; it is very acceptable to consider novel agents within clinical trials before chemotherapy is considered (see Table 12)
Chemotherapy	Choice of chemotherapy regimens is extensive (see Table 11), and choice depends on patient tolerance, risk of infection versus the relatively short duration of remission observed with most chemotherapy regimens; transplantation may be considered in highly selected persons

*For more details and detailed references, we refer the reader to the EORTC consensus recommendations for the treatment of mycosis fungoides/Sézary syndrome.[7]

syndrome, fever, and fluid retention, and so this is likely to remain a second- or third-line therapy. Recent evidence indicates that durable responses are also seen in patients with $CD25^-$ disease.[73] It has been successfully combined with bexarotene.[74]

HDACi

Histone deacetylase inhibitors have activity in various hematologic malignancies, including myeloid malignancies, Hodgkin lymphoma, peripheral T-cell lymphoma, and CTCL.[75,76] Vorinostat (suberoylanilide hydroxamic acid) is an orally available hydroxamic acid derivative that inhibits both class I and II histone deacetylases and has been approved in the United States by the Food and Drug Administration for the treatment of relapsed and refractory CTCL.[77] In the initial phase 2 study, there was an overall response rate of 24%, with a reduction in pruritus seen in 58% of patients.[78] In a subsequent trial, a 30% RR was observed in patients with stage IIB or higher disease.[79] The most common toxicities are gastrointestinal or constitutional symptoms, hematologic abnormalities, or taste disorders, and are usually of mild to moderate severity and typically manageable.[80] Other HDACi in development, such as romidedpsin (depsipeptide),[81] panobinostat,[82] and belinostat,[83] have demonstrated responses in MF/SS.

Monoclonal antibodies

Alemtuzumab, the humanized monoclonal antibody targeted against CD52w (a pan-lymphocyte antigen) has demonstrated efficacy in MF/SS; however, patients on trials to date have generally been very heavily pretreated, which have probably impacted on the relatively short duration of response and the substantial cytomegalovirus reactivation and hematologic toxicity observed.[84-88] Trials of combination strategies in less-heavily pretreated patients are warranted. In general, outside the clinical trial setting, it has a very limited place in the treatment of MF/SS. Hopefully, more T cell–

Table 9. Recommendations for treatment of stage III or SS (stages III or IVa)

Treatment	Comments*
First-line	
ECP	Well tolerated with limited toxicities; circulating T-cell clone should be detectable in blood by morphology, flow cytometry, or molecular studies; should not be considered in patients with SS who have extensive nodal (IVa) or visceral (IVb) disease; side effects to methoxsalen is rare; requires good venous access with the associated risk of infection; often combined with oral steroids (short-term), IFN-α, bexarotene, or low-dose MTX; improvement with ECP alone can take some weeks and maximum improvement may not be seen for many months; durable responses are not uncommon
IFN-α	Major difficulty is tolerance and compliance; some responses can be very durable; somewhat inconvenient (daily subcutaneous injection); most common side effect is fatigue, particularly in older patients; requires moderately high doses aiming for 3 to 5+ MU/day; monitor FBC and thyroid function; IFN-α can also be combined with PUVA, retinoids, bexarotene, and ECP
PUVA + IFN-α	For stage III disease; would not generally recommend PUVA alone; requires regular 2 or 3 times/week treatment and limited number of sites in nonmetropolitan areas
MTX	See Table 7 for comments
Second-line	
Bexarotene	See Table 7 for comments; can consider adding to ECP or IFN-α
Vorinostat	See Table 7 for comments; no data available of adding to ECP or IFN-α
Denileukin diftitox	See Table 7 for comments
Alemtuzumab	See Table 10 for comments
Novel agents within clinical trials	In patients with SS, chemotherapy is recommended after bexarotene and/or and HDACi and/or DD; it is very acceptable to consider novel agents within clinical trials before chemotherapy is considered (see Table 12)
Chemotherapy	Choice of chemotherapy regimens is extensive (see Table 11), and choice depends on patient tolerance, risk of infection versus the relatively short duration of remission observed with most chemotherapy regimens; transplantation may be considered in highly selected individuals

FBC indicates fludarabine, busulphan, and alemtuzumab.
*For more details and detailed references, we refer the reader to the EORTC consensus recommendations for the treatment of mycosis fungoides/Sézary syndrome.[7]

From bloodjournal.hematologylibrary.org by guest on May 27, 2012. For personal use only.

Table 10. Recommendations for treatment of MF stages IVA-IVB: first-line

Treatment	Comments*
Chemotherapy	Choice of chemotherapy regimens is extensive (see Table 11), and choice depends on patient tolerance, risk of infection versus the relatively short duration of remission observed with most chemotherapy regimens; autologous or allogeneic transplantation should be considered early in treatment paradigm for selected persons
TSEB and/or X-irradiation	Patients with advanced-stage disease may benefit from TSEB; "boosts" to site of thickened plaques/tumors; TSEB has limited availability; can take 6 to 10 weeks to complete; conventional radiation therapy can be valuable for local control of tumors or localized/bulky nodal disease
Bexarotene	See Table 7 for comments; few patients on clinical trials had stage IVB disease; thus, response rate and response durations are not well described
Denileukin diftitox	See Table 7 for comments; few patients on clinical trials had stage IVB disease; thus, response rate and response durations are not well described
IFN-α	See Table 7 for comments; less used in this stage of disease but may be helpful in patients unable to tolerate chemotherapy
Alemtuzumab	Major toxicity is immune suppression with infection; requires surveillance for cytomegalovirus and antimicrobial prophylaxis; short responses if used in multirelapsed disease so should consider early
Vorinostat	See Table 7 for comments; few patients on clinical trials had stage IVB disease; thus, response rate and response durations are not well described
Novel agents within clinical trials	Given poor prognosis and incurable nature of advanced-stage disease, it is very acceptable to consider novel agents within clinical trials before chemotherapy is considered (see Table 12)
Low-dose MTX	Generally well tolerated and convenient (oral weekly); dose-response effect is common and usually starts at 20 to 30 mg/week (up to 60-70 mg/week); some responses can be very durable; most common side effects are cytopenias and long-term risk of liver disease; very effective in patients with coexistent lymphomatoid papulosis; anecdotal experience that can be very useful in $CD30^+$ MF or $CD30^+$ transformed disease; can be used in conjunction with other therapies, such as steroids, ECP, and PUVA

*For more details and detailed references, we refer the reader to the EORTC consensus recommendations for the treatment of mycosis fungoides/Sézary syndrome.[7]

specific antibodies will be developed with less immunosuppressive effects. For example, zanolimumab (HuMax-CD4) is a fully humanized anti-CD4 monoclonal antibody and is specific for the CD4 receptor expressed on most T lymphocytes. Although the antibody interferes with T-cell activation, infections are uncommon. Single-agent response rates are more than or equal to 50%, but remission duration is relatively short.[89] Combination studies would be interesting but, to our knowledge, are currently not being investigated in CTCL.

Systemic chemotherapy

Several chemotherapy agents have demonstrated activity in MF/SS. We refer the reader to a detailed and comprehensive review of systemic chemotherapy in CTCL (Table 11).[90] In brief, systemic agents include alkylating agents (cyclophosphamide, chlorambucil), anthracyclines, purine analogs, and etoposide. Whereas single-agent or combination chemotherapy regimens have produced moderately high response rates in patients with advanced-stage MF/SS, these responses are typically not durable. There is no recognized superior multiagent chemotherapy regimen for MF, and regimens that are typically associated with the treatment of B-cell lymphoma or Hodgkin lymphoma, such as those using cyclophosphamide, vincristine, vinblastine, prednisolone, MTX, doxorubicin, or mechlorethamine, have a disappointing track record in MF/SS. For example, a study of infusional EPOCH (etoposide, vincristine, doxorubicin, bolus cyclophosphamide, and oral prednisone) in advanced refractory MF/SS demonstrated an overall response rate of

Table 11. Key clinical studies of systemic chemotherapy in cutaneous T-cell lymphoma

Therapy examples*	Efficacy	Comments
CHOP-based[67]	ORR stage IIB: 66%	Myelosuppression with risk of infection; very short remission duration
EPOCH[61]	ORR stage IIB-IV: 80%	Myelosuppression with risk of infection; short remission duration
CMED/ABV[42,62]	ORR stage III-IV: 81%	Myelosuppression with risk of infection; median DFS of 7 months and 27% 5-year DFS
Pegylated liposomal doxorubicin[65]	ORR stage IA-IV: 88%	Single agent; well tolerated; infusion-related events; no comparisons with standard anthracyclines
Pentostatin[64]	ORR stage IIB: 75% Stage III: 58% Stage IV: 50%	Numerous trials and regimens used; activity in PTCL; perhaps best activity in SS; prolonged therapy needed in some cases; lymphopenia
Fludarabine plus IFN-α[55]	ORR stage IIA-IVA: 58% stage IVB: 40%	Neutropenia common
Fludarabine plus cyclophosphamide[66]	ORR stage IIB-III: 55%	Appears higher RR to fludarabine-alone; lymphopenia and prolonged myelosuppression in some patients; stem cell collection yields are lower
Gemcitabine[63]	ORR stage IIB-III: 70%	Neutropenia; recent evidence that toxicities (rash, infection) may be higher in patients with CTCL (see "Systemic chemotherapy")
2-Chlorodeoxyadensine[68]	ORR stage IIA-IV: 28%	Median duration or response of 4.5 months; bone marrow suppression and infections in 62%

CR indicates complete response; CRR, complete response rate; EPOCH, etoposide, vincristine, doxorubicin, cyclophosphamide, and prednisone; ORR, overall response rate; PR, partial response; PUVA, ultraviolet A light with oral methoxypsoralen; and DFS, disease-free survival.

*See "Systemic chemotherapy" for more details and other trial results.

From bloodjournal.hematologylibrary.org by guest on May 27, 2012. For personal use only.

Table 12. Selected novel drugs being evaluated in current clinical trials for MF/SS

Drug class	Examples	Comments
HDACi	Romidepsin[81] Panobinostat[110] Belinostat[83]	Vorinostat is approved for relapsed, refractory CTCL, which has led to investigation to other HDACi in CTCL and PTCL; a number are undergoing regulatory approval process; response rates and toxicities are similar
Monoclonal antibodies	Zanolimumab[89]	ORR of 50%+ as single agent in early studies but of relatively short duration; well tolerated with little infection risk; combination studies planned
	Alemtuzumab[84-86,88]	Single-agent studies with ORR of 40%+ but short duration; immunosuppressive; combination studies underway
Purine nucleoside phosphorylase inhibitor	Forodesine (BCX-1777)[111]	Single-agent activity of 30%+ with durable remissions observed; well tolerated and convenient (oral)
Proteasome inhibitors	Bortezomib[112]	Single-agent activity observed in heavily pretreated patients; generally well tolerated with minimal myelosuppression; combination studies planned
IMiDs	Lenalidomide[113]	Single-agent activity observed in heavily pretreated patients; generally well tolerated, but fatigue appears dose-limiting; maintenance studies being considered
Synthetic oligodeoxynucleotides containing unmethylated CG dinucleotides (CpG-ODN)	PF-3512676	CpG-ODN have potent immunostimulatory effects and activate professional antigen-presenting cells that express the target receptor, Toll-like receptor 9[114]
Retinoids	Tazarotene[115]	Novel synthetic retinoid
Fusion toxins	Anti-Tac(Fv)-PE38 (LMB-2)[116]	Fusion toxins, which combines a target cell binding domain linked to a bacterial toxin
Antifolate	Pralatrexate[117]	Pralatrexate is a novel antifolate designed to have high affinity for the reduced folate carrier type 1

IMiDs indicates immunomodulatory drugs; and CpG-ODN, cytosine-phosphate-guanosine oligodeoxynucleotide.

80% with 27% CRs[61]; however, the median duration of response was just 8 months (range, 3-22 months). This study also highlighted the problem of infectious complications in the delivery of chemotherapy in patients whose disease renders them inherently immune-suppressed and who are frequently colonized with potentially pathogenic bacteria.[91,92] The combination therapy of cyclophosphamide, MTX, etoposide, dexamethasone alternating with doxorubicin, bleomycin, and vinblastine is suitable for selected younger patients and has demonstrated a 5-year disease-free survival of 27%.[42,62]

Because of the high risk of infection and myelosuppression and modest response durations with combination chemotherapy, single-agent therapies are preferred, except in patients who are refractory or who present with extensive adenopathy and/or visceral involvement or constitutional symptoms and require rapid tumor reduction. Thus, in patients with relatively slowly progressive disease who have failed other treatments, we would consider low-dose oral MTX, chlorambucil, cyclophosphamide, or etoposide. For patients with more rapidly progressive disease and of reasonable performance status, our preference is to use single-agent gemcitabine,[63,93-95] pentostatin,[54,64,96-100] or liposomal doxorubicin[65,101,102] as these agents have been investigated the most thoroughly. Gemcitabine has a high response rate, but myelosuppression can be problematic with dose-reduction frequently required. A recent report suggests that patients with CTCL may be more prone to other nonhematopoietic toxicities of this drug.[95] Overall response rates as high as 70% have been reported for pentostatin with a variety of regimens used. However, such high response rates are generally observed in patients with SS with lower response rates expected in patients with tumor stage or nodal disease. Infectious complications can be reduced with prophylactic trimethoprim and antiviral therapies.[64] It has been combined with IFN-α with improvement in progression-free survival. Single-agent fludarabine has a poor response rate of less than 20%, but one combination strategy that appears promising is fludarabine with cyclophosphamide (Table 11). However, short- and long-term hematologic toxicity can be problematic.[66]

Transplantation

Interpretation of the transplantation data are difficult because the number of patients with MF/SS treated to date with stem cell transplantation is very small. A review of this subject has recently been published.[103] In brief, standard-intensity allogeneic stem cell transplantation has been shown to induce complete and durable remissions in patients with CTCL; however, infection rates are high.[104-106] Investigators have been evaluating reduced-intensity conditioning for MF/SS and transplantation-related mortality is low, time to relapse is variable, and durable remissions are observed.[107,108] We recommend that allogeneic transplantation be considered in younger patients with advanced-stage disease if not responding to agents such as IFN-α, bexarotene, HDACi, or denileukin diftitox.

Results with autologous stem cell transplantation have not been particularly promising.[103,109] However, despite the limited data, in younger patients with stage IIB, stage IV, or transformed disease who are refractory/relapsed after IFN-α, bexarotene, or HDACi, their outcome is extremely poor and aggressive approaches seem warranted.[5] High-dose therapy has the potential to increase response, and it has been our observation that, although virtually all patients relapse, some patients relapse with somewhat more indolent disease that in turn is more easily managed with nonchemotherapy agents. Clearly, more investigation is required for this group of patients.

Novel agents within clinical trials

In the last few years, several new agents have become available for the treatment of MF. These include bexarotene, denileukin diftitox, and vorinostat. For patients who are not suitable or fail these drugs, novel agents within clinical trials should always be considered. Indeed, it is our belief that patients should be considered for clinical trials as an alternative strategy to systemic chemotherapy. Novel agents that are being investigated in the context of clinical trials are listed in Table 12.

From bloodjournal.hematologylibrary.org by guest on May 27, 2012. For personal use only.

Figure 4. Patient with stage IIB disease with large tumor on the left calf.

Clinical case 3: progressive disease despite SDT

Scenario

A 52-year-old male patient presented with an 18-month history of polymorphic patches and plaques involving the limbs and pelvic girdle area, which had been partially controlled with topical steroids and attributed to "psoriasis." A diagnosis of MF was made on the basis of diagnostic clinical and pathologic features (stage IB; Figure 4).

Management

Phototherapy was initiated with initial success, but the patient developed an ulcerated tumor on the right calf, which histologically showed scattered large blastlike cells ($CD30^-$). A staging CT scan was normal. The tumor responded to radiotherapy and PUVA was continued with an excellent response, allowing withdrawal of therapy after 5 months. The patient remained well for 5 years despite developing on average 2 small- to medium-sized tumors every 18 months, which responded to further radiotherapy. However, a recurrence of extensive cutaneous patches and plaques was noted to have gradually developed at routine clinic review, and examination revealed a bulky axillary node (3 cm), which histologically showed partial effacement with malignant lymphocytes. A CT scan showed no other abnormality and the patient (with now "stage IVA disease") was treated with CHOP chemotherapy (cyclophosphamide, doxorubicin, vincristine, prednisone). An initial complete response after 2 cycles was followed by a recurrence of extensive cutaneous disease (characterized by patches/plaques and scattered tumors) after 4 cycles despite complete resolution of the nodal disease. Chemotherapy was discontinued, the patient was entered into a clinical trial, and a donor search for reduced-intensity conditioning allogeneic transplantation was initiated.

Comment

This case emphasizes the clinical heterogeneity of MF and the challenge of deciding when to escalate therapy as some patients with advanced but limited disease (stage IIB) can be successfully managed with SDT, including radiotherapy, whereas extensive skin tumors (stage IIB) or nodal disease (stage IVA) invariably require aggressive therapies, including chemotherapy and consideration of high-dose therapies, including allogeneic transplantation if the patient's performance status is satisfactory.

Transformed disease

Although most patients with early-stage disease (patches or plaques confined to the skin) have an indolent course, progression to cutaneous tumors, nodal, or visceral disease can occur. Cutaneous tumors can develop either as increasing depth of the small atypical lymphocytes of MF or as a result of large-cell transformation. Thus, when a patient presents with a tumor nodule, it is critical to biopsy the lesion as treatment and outcomes for advanced-stage disease versus transformed disease are quite different (Figure 5). Large-cell transformation is currently defined as large cells ($\geq$ 4 times the size of a small lymphocyte) in more than 25% of the infiltrate or if these cells formed microscopic nodules.[118,119] There is a variable incidence of transformation from MF of 8% to 39% reported, and it is associated with a very poor prognosis with a median survival of less than 2 years with particularly short survival in those patients who transform early after diagnosis. The risk of transformation is associated with advanced-stage, elevated β2-microglobulin and elevated lactate dehydrogenase[9,118] (Table 13).

Treatment of transformed disease is a major challenge as these patients generally have a poor outcome. Prognosis is particularly poor when patients have multiple sites of large-cell transformation. There are limited preliminary data to indicate that some patients with advanced-stage disease in whom the large cells express CD30 may have a more indolent course.[9,120] For the younger patient, systemic chemotherapy is initiated early and consideration should be made for autologous or allogeneic transplantation. Consolidative radiation therapy should be considered in young patients with unifocal transformation. In elderly or frail patients with unifocal disease, local radiation therapy should be used and occasionally may result in durable remissions.

From bloodjournal.hematologylibrary.org by guest on May 27, 2012. For personal use only.

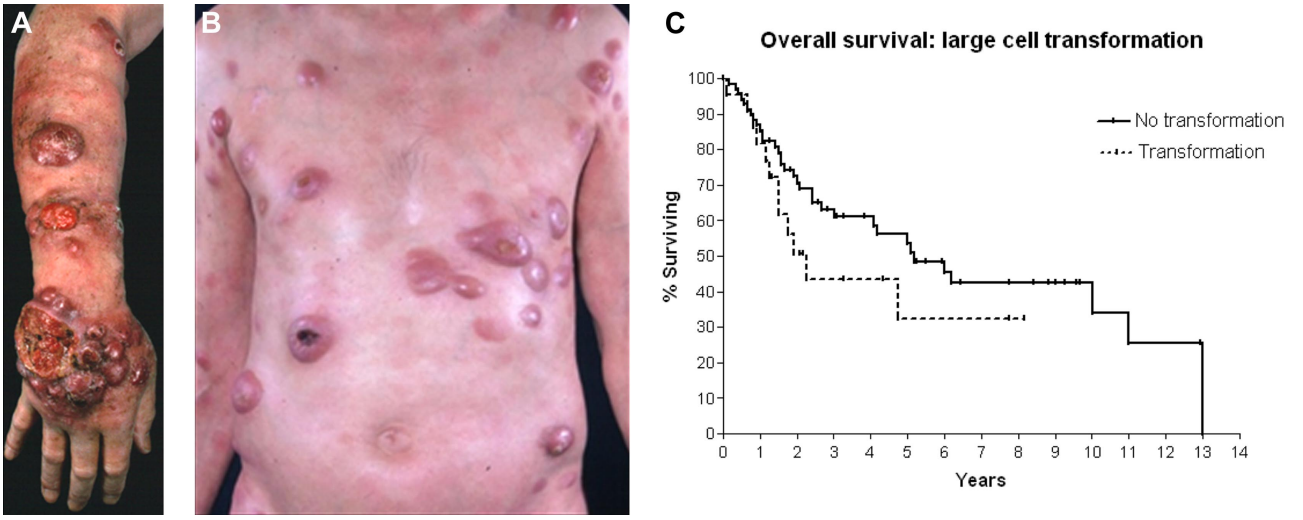

Figure 5. Patient with MF with transformed disease. (A) On limbs. (B) On trunk. (C) OS of patients with advanced-stage disease according to the presence (n = 22) or absence (n = 70) of large-cell transformation in the advanced-stage population.[9] Median OS in the transformed group was 2.2 years, compared with 5.2 years in the nontransformed group.

Clinical case 4: transformed disease—is it or is it not?

Scenario

This 40-year-old woman presented with a 2-year history of erythematous patches and plaques over the pelvic girdle area and limbs, which was initially considered to be eczema by her local medical officer. She then presented with a 2-month history of small tumors on the trunk. A diagnostic biopsy showed an infiltrate of large $CD30^+$ anaplastic cells and staging investigations were normal, suggesting a diagnosis of primary cutaneous $CD30^+$ anaplastic lymphoma. However, a biopsy of the "eczematous" rash showed an epidermotropic infiltrate of $CD4^+$ T cells consistent with MF. In addition, closer discussion with the patient revealed a history of recurrent nodules and small tumors, which always resolved to leave varioliform scars. The diagnosis was changed to MF (stage IB) with LyP. Identical T-cell clones were detected in biopsies from the patches/plaques and the tumor (Figure 6).

Management

The presenting tumor was treated with local radiotherapy, and the patient achieved a complete response to PUVA phototherapy after 4 months of therapy. Subsequently, she remained off therapy with only topical emollients, but frequent recurrences of self-healing papules and nodules prompted successful maintenance treatment with low-dose oral MTX.

Table 13. Distribution of patients with large-cell transformation, according to stage of MF/SS[9]

Stage/subtype	Patients, n	Transformed patients, n	Transformed patients, %
IA/IB/IIA	208	3	1.4
IIB	41	11	26.8
III	36	1	2.8
IVA	9	5	55.6
IVB	3	2	66.7
Total	297	22	7.4

Comment

This case illustrates the critical need for expert clinical and pathologic correlation to make the correct diagnosis and avoid inappropriate aggressive therapy. MF is often associated with LyP, and treatment/prognosis is based on the stage of MF. Such patients have to be distinguished from those patients with MF who develop disease progression characterized by tumors with large-cell transformation (dermal sheeted nodules of large pleomorphic or anaplastic blast-like cells, which may or may not be $CD30^+$). Moreover, we think that the current pathologic criteria for large-cell transformation in MF are inadequate and need to be further clarified to aid in distinguishing the various entities.

Sézary syndrome

SS is currently defined by the ISCL as a distinctive erythrodermic CTCL with hematologic evidence of leukemic involvement[121] (Figure 7). The WHO-EORTC considers SS to be a separate entity from cases that otherwise meet the criteria for SS but have been preceded by clinically typical MF.[1,122] Such latter cases have been designated as "SS preceded by MF" and also as "secondary" SS.[123] Patients with SS can be classified either as stage III or IV. The median survival of classic SS in one report of 62 patients was 31 months with a 5-year survival of 34%.[124] It appears that the overall prognosis of SS/erythrodermic MF (E-CTCL) is improving; and in a recent report of 124 patients with E-CTCL, there was a median OS of 5.1 years (range, 0.4-18.6 years).[125] When patients were stratified according to Sézary cell (SC) counts, the median OS was 7.6 years for patients with less than 1000 SC/L versus 2.4 years for those with more than 10 000 SC/L. In multivariate analysis, advanced age and elevated lactate dehydrogenase were the strongest predictors of a poor prognosis.[125] In another study of 106 patients with erythrodermic MF, median survival ranged from 1.5 to 10.2 years depending on the presence of 3 independent adverse factors: patient age, presence of lymph node disease, and peripheral blood involvement.[126]

Patients with E-CTCL present a difficult management problem because they often have severe itch and a high risk of infection

From bloodjournal.hematologylibrary.org by guest on May 27, 2012. For personal use only.

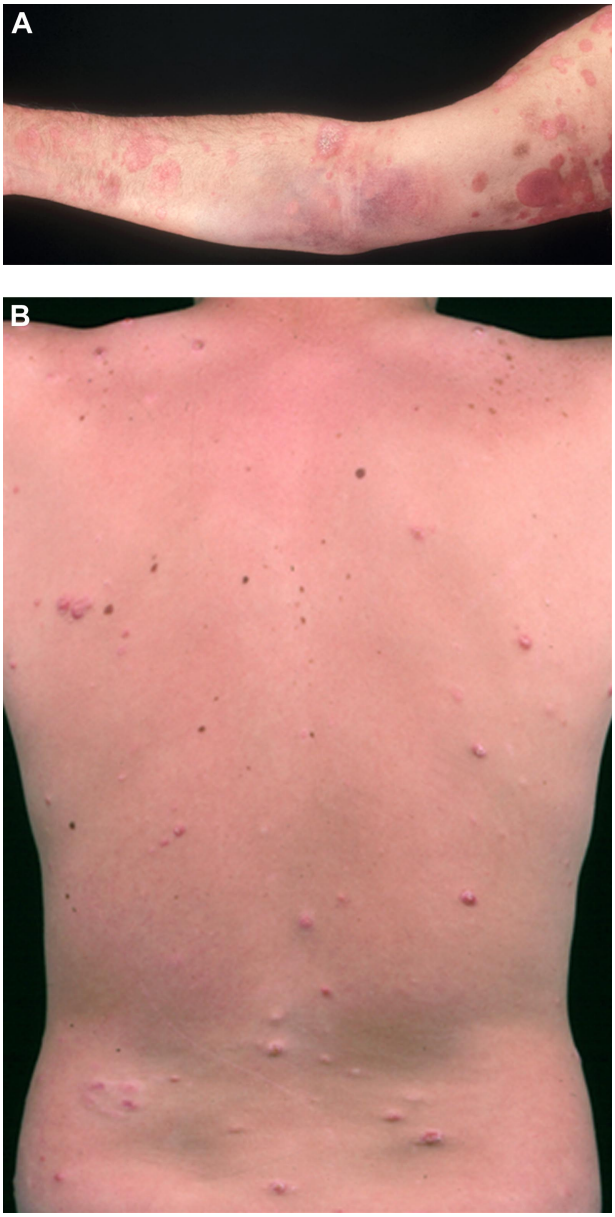

Figure 6. Patient with patches and plaques of MF (stage IB) on the limbs and self-healing papules and nodules of lymphomatoid papulosis on the trunk.

Figure 7. Patient with SS with erythrodermic disease.

complicating therapy, and remission durations after therapy are frequently short. In general terms, the treatment is similar to that of advanced-stage MF. Systemic therapy or TSEB is often required if PUVA therapy fails. However, patients with erythroderma are exquisitely sensitive to radiation therapy, and planned doses may have to be reduced. In patients with E-CTCL, it is always important to consider underlying staphylococcal infection "driving" disease exacerbation. Indeed, it is well recognized that recognition and treatment of underlying infection (which is often not clinically evident) will result in clinical improvement in the patient's erythroderma.[92,127]

One treatment that is more effective in E-CTCL compared with other stages of MF is ECP. The efficacy of ECP in E-CTCL has been reviewed elsewhere, and these reviews are highly recommended.[128-130] In brief, phase 2 studies have reported a therapeutic benefit of ECP in CTCL, although the response data have been variable, ranging from 30% to 80% depending on study entry criteria, patient selection, and intervals between diagnosis and treatment. No phase 3 (randomized) trials have been performed.

In line with the United Kingdom consensus guidelines, we recommend that patients with E-CTCL with circulating lymphocytes (molecular, flow, or morphology) have an initial trial with ECP.[130] The regimens used are variable[131] but in general require an intense induction and then maintenance phase.[130] Responses may take 6 months or more. Improved RR has been reported when used in combination with bexarotene, PUVA, and IFN-α. In general, we recommend combining ECP with bexarotene or IFN-α.

Second-line therapy for E-CTCL is detailed in Table 9. Patients with E-CTCL have been well represented in clinical trials of bexarotene, denileukin diftitox, HDACi, and alemtuzumab; and indeed, in several trials patients with erythroderma appear to have a better outcome than nodal or tumor-stage disease with such strategies. Chemotherapy, including transplantation strategies, should be considered in younger patients. Single-agent chemotherapy regimens, such as gemcitabine or pentostatin, are our preferred chemotherapy choices (Table 11).

Summary

The first step in managing MF/SS is obtaining an accurate diagnosis, which always requires good communication between the clinician and pathologist. In some instances, close observation and repeated biopsies may be needed. Treatment requires an individualized approach largely depending on the stage of disease and

From bloodjournal.hematologylibrary.org by guest on May 27, 2012. For personal use only.

performance status of the patient. Overaggressive therapy with multiagent chemotherapy should be avoided, particularly in patients with early-stage MF/SS. Exciting novel targeted therapies are under investigation, which will add to the armamentarium of treatments for this challenging group of diseases.

Authorship

Contribution: H.M.P., S.W., and R.T.H. wrote the paper.

Conflict-of-interest disclosure: H.M.P. is a consultant to Merck, Novartis, Gloucester Pharmaceuticals, Eisai, and has received research funding from Merck, Novartis, and Gloucester Pharmaceuticals. S.W. is a consultant for Gloucester Pharmaceuticals, Eisai, and Merck. R.T.H. declares no competing financial interests.

Correspondence: H. Miles Prince, Division of Haematology and Medical Oncology, Peter MacCallum Cancer Institute, Locked Bag 1, A'Beckett St, Melbourne 8006, Victoria, Australia; e-mail: miles.prince@petermac.org.

References

1. Willemze R, Jaffe ES, Burg G, et al. WHO-EORTC classification for cutaneous lymphomas. *Blood.* 2005;105(10):3768-3785.
2. Bradford PT, Devesa SS, Anderson WF, Toro JR. Cutaneous lymphoma incidence patterns in the United States: a population-based study of 3884 cases. *Blood.* 2009;113(21):5064-5073.
3. Jaffe E, Harris N, Stein H, Vardiman J. *World Health Organization Classification of Tumours: Pathology and Genetics of Tumours of Haematopoietic and Lymphoid Tissues.* Lyon, France: IARC Press; 2001.
4. Willemze R, Kerl H, Sterry W, et al. EORTC classification for primary cutaneous lymphomas: a proposal from the Cutaneous Lymphoma Study Group of the European Organization for Research and Treatment of Cancer. *Blood.* 1997; 90(1):354-371.
5. Horwitz SM, Olsen EA, Duvic M, Porcu P, Kim YH. Review of the treatment of mycosis fungoides and Sezary syndrome: a stage-based approach. *J Natl Compr Canc Netw.* 2008;6(4):436-442.
6. Dummer R, Dreyling M. Primary cutaneous lymphoma: ESMO clinical recommendations for diagnosis, treatment and follow-up. *Ann Oncol.* 2008;19[suppl 2]:72-76.
7. Trautinger F, Knobler R, Willemze R, et al. EORTC consensus recommendations for the treatment of mycosis fungoides/Sezary syndrome. *Eur J Cancer.* 2006;42(8):1014-1030.
8. Pimpinelli N, Olsen EA, Santucci M, et al. Defining early mycosis fungoides. *J Am Acad Dermatol.* 2005;53(6):1053-1063.
9. Arulogun SO, Prince HM, Ng J, et al. Long-term outcomes of patients with advanced-stage cutaneous T-cell lymphoma and large-cell transformation. *Blood.* 2008;112(8):3082-3087.
10. Yen A, McMichael A, Rotstein H. Mycosis fungoides: an Australian experience. *Australas J Dermatol.* 1997;38[suppl]:S86-S90.
11. Olsen E, Vonderheid E, Pimpinelli N, et al. Revisions to the staging and classification of mycosis fungoides and Sezary syndrome: a proposal of the International Society for Cutaneous Lymphomas (ISCL) and the cutaneous lymphoma task force of the European Organization of Research and Treatment of Cancer (EORTC). *Blood.* 2007; 110(6):1713-1722.
12. Kim YH, Liu HL, Mraz-Gernhard S, Varghese A, Hoppe RT. Long-term outcome of 525 patients with mycosis fungoides and Sezary syndrome: clinical prognostic factors and risk for disease progression. *Arch Dermatol.* 2003;139(7):857-866.
13. Zackheim HS, Amin S, Kashani-Sabet M, McMillan A. Prognosis in cutaneous T-cell lymphoma by skin stage: long-term survival in 489 patients. *J Am Acad Dermatol.* 1999;40(3):418-425.
14. van Doorn R, Van Haselen CW, van Voorst Vader PC, et al. Mycosis fungoides: disease evolution and prognosis of 309 Dutch patients. *Arch Dermatol.* 2000;136(4):504-510.
15. Diamandidou E, Cohen PR, Kurzrock R. Mycosis fungoides and Sezary syndrome. *Blood.* 1996; 88(7):2385-2409.
16. Kaye FJ, Bunn PA Jr, Steinberg SM, et al. A randomized trial comparing combination electron-beam radiation and chemotherapy with topical therapy in the initial treatment of mycosis fungoides. *N Engl J Med.* 1989;321(26):1784-1790.
17. van Doorn R, Scheffer E, Willemze R. Follicular mycosis fungoides, a distinct disease entity with or without associated follicular mucinosis: a clinicopathologic and follow-up study of 51 patients. *Arch Dermatol.* 2002;138(2):191-198.
18. Gerami P, Rosen S, Kuzel T, Boone SL, Guitart J. Folliculotropic mycosis fungoides: an aggressive variant of cutaneous T-cell lymphoma. *Arch Dermatol.* 2008;144(6):738-746.
19. Willemze R. Prognostic factors in cutaneous T cell lymphoma. *Hematol Meeting Rep.* 2009; 3(1):123-130.
20. Vermeer MH, van Doorn R, Dukers D, Bekkenk MW, Meijer CJ, Willemze R. CD8+ T cells in cutaneous T-cell lymphoma: expression of cytotoxic proteins, Fas ligand, and killing inhibitory receptors and their relationship with clinical behavior. *J Clin Oncol.* 2001;19(23):4322-4329.
21. Abeni D, Frontani M, Sampogna F, et al. Circulating CD8+ lymphocytes, white blood cells, and survival in patients with mycosis fungoides. *Br J Dermatol.* 2005;153(2):324-330.
22. Zackheim HS, Kashani-Sabet M, Amin S. Topical corticosteroids for mycosis fungoides: experience in 79 patients. *Arch Dermatol.* 1998;134(8):949-954.
23. Herrmann JJ, Roenigk HH, Hurria A, et al. Treatment of mycosis fungoides with photochemotherapy (PUVA): long-term follow-up. *J Am Acad Dermatol.* 1995;33(2):234-242.
24. Berthelot C, Rivera A, Duvic M. Skin directed therapy for mycosis fungoides: a review. *J Drugs Dermatol.* 2008;7(7):655-666.
25. Lindelof B, Sigurgeirsson B, Tegner E, et al. PUVA and cancer risk: the Swedish follow-up study. *Br J Dermatol.* 1999;141(1):108-112.
26. Stern RS, Laird N, Melski J, Parrish JA, Fitzpatrick TB, Bleich HL. Cutaneous squamous-cell carcinoma in patients treated with PUVA. *N Engl J Med.* 1984;310(18):1156-1161.
27. Stern RS, Nichols KT, Vakeva LH. Malignant melanoma in patients treated for psoriasis with methoxsalen (psoralen) and ultraviolet A radiation (PUVA): the PUVA Follow-Up Study. *N Engl J Med.* 1997;336(15):1041-1045.
28. Hofer A, Cerroni L, Kerl H, Wolf P. Narrowband (311-nm) UV-B therapy for small plaque parapsoriasis and early-stage mycosis fungoides. *Arch Dermatol.* 1999;135(11):1377-1380.
29. Gathers RC, Scherschun L, Malick F, Fivenson DP, Lim HW. Narrowband UVB phototherapy for early-stage mycosis fungoides. *J Am Acad Dermatol.* 2002;47(2):191-197.
30. Rupoli S, Barulli S, Guiducci B, et al. Low dose interferon-alpha2b combined with PUVA is an effective treatment of early stage mycosis fungoides: results of a multicenter study. Cutaneous-T Cell Lymphoma Multicenter Study Group. *Haematologica.* 1999;84(9):809-813.
31. Stadler R, Otte HG, Luger T, et al. Prospective randomized multicenter clinical trial on the use of interferon-2a plus acitretin versus interferon-2a plus PUVA in patients with cutaneous T-cell lymphoma stages I and II. *Blood.* 1998;92(10):3578-3581.
32. Thomsen K, Hammar H, Molin L, Volden G. Retinoids plus PUVA (RePUVA) and PUVA in mycosis fungoides, plaque stage: a report from the Scandinavian Mycosis Fungoides Group. *Acta Derm Venereol.* 1989;69(6):536-538.
33. Quiros PA, Jones GW, Kacinski BM, et al. Total skin electron beam therapy followed by adjuvant psoralen/ultraviolet-A light in the management of patients with T1 and T2 cutaneous T-cell lymphoma (mycosis fungoides). *Int J Radiat Oncol Biol Phys.* 1997;38(5):1027-1035.
34. Deeths MJ, Chapman JT, Dellavalle RP, Zeng C, Aeling JL. Treatment of patch and plaque stage mycosis fungoides with imiquimod 5% cream. *J Am Acad Dermatol.* 2005;52(2):275-280.
35. Hoppe RT. Mycosis fungoides: radiation therapy. *Dermatol Ther.* 2003;16(4):347-354.
36. Kim JH, Nisce LZ, D'Anglo GJ. Dose-time fractionation study in patients with mycosis fungoides and lymphoma cutis. *Radiology.* 1976;119(2):439-442.
37. Wilson LD, Kacinski BM, Jones GW. Local superficial radiotherapy in the management of minimal stage IA cutaneous T-cell lymphoma (mycosis fungoides). *Int J Radiat Oncol Biol Phys.* 1998; 40(1):109-115.
38. Hoppe RT, Fuks Z, Bagshaw MA. The rationale for curative radiotherapy in mycosis fungoides. *Int J Radiat Oncol Biol Phys.* 1977;2(9):843-851.
39. Chinn DM, Chow S, Kim YH, Hoppe RT. Total skin electron beam therapy with or without adjuvant topical nitrogen mustard or nitrogen mustard alone as initial treatment of T2 and T3 mycosis fungoides. *Int J Radiat Oncol Biol Phys.* 1999; 43(5):951-958.
40. Wilson LD, Jones GW, Kim D, et al. Experience with total skin electron beam therapy in combination with extracorporeal photopheresis in the management of patients with erythrodermic (T4) mycosis fungoides. *J Am Acad Dermatol.* 2000; 43(1):54-60.
41. Knobler RM, Trautinger F, Radaszkiewicz T, Kokoschka EM, Micksche M. Treatment of cutaneous T cell lymphoma with a combination of low-dose interferon alfa-2b and retinoids. *J Am Acad Dermatol.* 1991;24(2):247-252.
42. Duvic M, Lemak NA, Redman JR, et al. Combined modality therapy for cutaneous T-cell lymphoma. *J Am Acad Dermatol.* 1996;34(6):1022-1029.
43. Zachariae H, Grunnet E, Thestrup-Pedersen K, et al. Oral retinoid in combination with bleomycin, cyclophosphamide, prednisone and transfer factor in mycosis fungoides. *Acta Derm Venereol.* 1982;62(2):162-164.
44. Burg G, Dummer R. Historical perspective on the use of retinoids in cutaneous T-cell lymphoma

From bloodjournal.hematologylibrary.org by guest on May 27, 2012. For personal use only.

(CTCL). *Clin Lymphoma.* 2000;1[suppl 1]:S41-S44.

45. Zhang C, Duvic M. Retinoids: therapeutic applications and mechanisms of action in cutaneous T-cell lymphoma. *Dermatol Ther.* 2003;16(4):322-330.
46. Talpur R, Ward S, Apisarnthanarax N, Breuer-Mcham J, Duvic M. Optimizing bexarotene therapy for cutaneous T-cell lymphoma. *J Am Acad Dermatol.* 2002;47(5):672-684.
47. Breneman D, Duvic M, Kuzel T, Yocum R, Truglia J, Stevens VJ. Phase 1 and 2 trial of bexarotene gel for skin-directed treatment of patients with cutaneous T-cell lymphoma. *Arch Dermatol.* 2002;138(3):325-332.
48. Duvic M, Hymes K, Heald P, et al. Bexarotene is effective and safe for treatment of refractory advanced-stage cutaneous T-cell lymphoma: multinational phase II-III trial results. *J Clin Oncol.* 2001;19(9):2456-2471.
49. Duvic M, Martin AG, Kim Y, et al. Phase 2 and 3 clinical trial of oral bexarotene (Targretin capsules) for the treatment of refractory or persistent early-stage cutaneous T-cell lymphoma. *Arch Dermatol.* 2001;137(5):581-593.
50. Gniadecki R, Assaf C, Bagot M, et al. The optimal use of bexarotene in cutaneous T-cell lymphoma. *Br J Dermatol.* 2007;157(3):433-440.
51. Olsen EA. Interferon in the treatment of cutaneous T-cell lymphoma. *Dermatol Ther.* 2003;16(4):311-321.
52. Bunn PA Jr, Ihde DC, Foon KA. The role of recombinant interferon alfa-2a in the therapy of cutaneous T-cell lymphomas. *Cancer.* 1986;57[suppl 8]:1689-1695.
53. Olsen EA, Rosen ST, Vollmer RT, et al. Interferon alfa-2a in the treatment of cutaneous T cell lymphoma. *J Am Acad Dermatol.* 1989;20(3):395-407.
54. Foss FM, Ihde DC, Breneman DL, et al. Phase II study of pentostatin and intermittent high-dose recombinant interferon alfa-2a in advanced mycosis fungoides/Sezary syndrome. *J Clin Oncol.* 1992;10(12):1907-1913.
55. Foss FM, Ihde DC, Linnoila IR, et al. Phase II trial of fludarabine phosphate and interferon alfa-2a in advanced mycosis fungoides/Sezary syndrome. *J Clin Oncol.* 1994;12(10):2051-2059.
56. Kaplan EH, Rosen ST, Norris DB, Roenigk HH Jr, Saks SR, Bunn PA Jr. Phase II study of recombinant human interferon gamma for treatment of cutaneous T-cell lymphoma. *J Natl Cancer Inst.* 1990;82(3):208-212.
57. Duvic M, Sherman ML, Wood GS, et al. A phase II open-label study of recombinant human interleukin-12 in patients with stage IA, IB, or IIA mycosis fungoides. *J Am Acad Dermatol.* 2006;55(5):807-813.
58. Zackheim HS, Kashani-Sabet M, McMillan A. Low-dose methotrexate to treat mycosis fungoides: a retrospective study in 69 patients. *J Am Acad Dermatol.* 2003;49(5):873-878.
59. McDonald CJ, Bertino JR. Treatment of mycosis fungoides lymphoma: effectiveness of infusions of methotrexate followed by oral citrovorum factor. *Cancer Treat Rep.* 1978;62(7):1009-1014.
60. Aviles A, Nambo MJ, Neri N, et al. Interferon and low dose methotrexate improve outcome in refractory mycosis fungoides/Sezary syndrome. *Cancer Biother Radiopharm.* 2007;22(6):836-840.
61. Akpek G, Koh HK, Bogen S, O'Hara C, Foss FM. Chemotherapy with etoposide, vincristine, doxorubicin, bolus cyclophosphamide, and oral prednisone in patients with refractory cutaneous T-cell lymphoma. *Cancer.* 1999;86(7):1368-1376.
62. Duvic M, Apisarnthanarax N, Cohen DS, Smith TL, Ha CS, Kurzrock R. Analysis of long-term outcomes of combined modality therapy for cutaneous T-cell lymphoma. *J Am Acad Dermatol.* 2003;49(1):35-49.
63. Zinzani PL, Baliva G, Magagnoli M, et al. Gemcitabine treatment in pretreated cutaneous T-cell lymphoma: experience in 44 patients. *J Clin Oncol.* 2000;18(13):2603-2606.
64. Tsimberidou AM, Giles F, Duvic M, Fayad L, Kurzrock R. Phase II study of pentostatin in advanced T-cell lymphoid malignancies: update of an M.D. Anderson Cancer Center series. *Cancer.* 2004;100(2):342-349.
65. Wollina U, Dummer R, Brockmeyer NH, et al. Multicenter study of pegylated liposomal doxorubicin in patients with cutaneous T-cell lymphoma. *Cancer.* 2003;98(5):993-1001.
66. Scarisbrick JJ, Child FJ, Clift A, et al. A trial of fludarabine and cyclophosphamide combination chemotherapy in the treatment of advanced refractory primary cutaneous T-cell lymphoma. *Br J Dermatol.* 2001;144(5):1010-1015.
67. Molin L, Thomsen K, Volden G, et al. Combination chemotherapy in the tumour stage of mycosis fungoides with cyclophosphamide, vincristine, vp-16, adriamycin and prednisolone (COP, CHOP, CAVOP): a report from the Scandinavian mycosis fungoides study group. *Acta Derm Venereol.* 1980;60(6):542-544.
68. Kuzel TM, Hurria A, Samuelson E, et al. Phase II trial of 2-chlorodeoxyadenosine for the treatment of cutaneous T-cell lymphoma. *Blood.* 1996;87(3):906-911.
69. Eklund JW, Kuzel TM. Denileukin diftitox: a concise clinical review. *Expert Rev Anticancer Ther.* 2005;5(1):33-38.
70. Foss F. Clinical experience with denileukin diftitox (ONTAK). *Semin Oncol.* 2006;33[suppl 3]:S11-S16.
71. Olsen E, Duvic M, Frankel A, et al. Pivotal phase III trial of two dose levels of denileukin diftitox for the treatment of cutaneous T-cell lymphoma. *J Clin Oncol.* 2001;19(2):376-388.
72. Negro-Vilar A, Dziewanowska Z, Groves E, et al. Efficacy and safety of denileukin diftitox (Dd) in a phase III, double-blind, placebo-controlled study of CD25+ patients with cutaneous T-cell lymphoma (CTCL). *J Clin Oncol ASCO Annual Meeting Proceedings.* 2007;25:8026.
73. Talpur R, Jones DM, Alencar AJ, et al. CD25 expression is correlated with histological grade and response to denileukin diftitox in cutaneous T-cell lymphoma. *J Invest Dermatol.* 2006;126(3):575-583.
74. Talpur R, Duvic M. Treatment of mycosis fungoides with denileukin diftitox and oral bexarotene. *Clin Lymphoma Myeloma.* 2006;6(6):488-492.
75. Rasheed WK, Johnstone RW, Prince HM. Histone deacetylase inhibitors in cancer therapy. *Expert Opin Investig Drugs.* 2007;16(5):659-678.
76. Prince HM, Bishton MJ, Harrison SJ. Clinical studies of histone deacetylase inhibitors. *Clin Cancer Res.* 2009;15(12):3958-3969.
77. Mann BS, Johnson JR, Cohen MH, Justice R, Pazdur R. FDA approval summary: vorinostat for treatment of advanced primary cutaneous T-cell lymphoma. *Oncologist.* 2007;12(10):1247-1252.
78. Duvic M, Talpur R, Ni X, et al. Phase 2 trial of oral vorinostat (suberoylanilide hydroxamic acid, SAHA) for refractory cutaneous T-cell lymphoma (CTCL). *Blood.* 2007;109(1):31-39.
79. Olsen EA, Kim YH, Kuzel TM, et al. Phase IIb multicenter trial of vorinostat in patients with persistent, progressive, or treatment refractory cutaneous T-cell lymphoma. *J Clin Oncol.* 2007;25(21):3109-3115.
80. Mann BS, Johnson JR, He K, et al. Vorinostat for treatment of cutaneous manifestations of advanced primary cutaneous T-cell lymphoma. *Clin Cancer Res.* 2007;13(8):2318-2322.
81. Piekarz R, Frye R, Turner M, et al. A multi-institutional phase II trial of the HDAC inhibitor romidepsin as monotherapy for patients with cutaneous T-cell lymphoma. *J Clin Oncol.* In press.
82. Prince HM, Bishton MJ, Johnstone RW. Panobinostat (LBH589): a potent pan-deacetylase inhibitor with promising activity against hematologic and solid tumors. *Future Oncol.* 2009;5(5):601-612.
83. Gimsing P. Belinostat: a new broad acting antineoplastic histone deacetylase inhibitor. *Expert Opin Investig Drugs.* 2009;18(4):501-508.
84. Bernengo MG, Quaglino P, Comessatti A, et al. Low-dose intermittent alemtuzumab in the treatment of Sezary syndrome: clinical and immunologic findings in 14 patients. *Haematologica.* 2007;92(6):784-794.
85. Enblad G, Hagberg H, Erlanson M, et al. A pilot study of alemtuzumab (anti-CD52 monoclonal antibody) therapy for patients with relapsed or chemotherapy-refractory peripheral T-cell lymphomas. *Blood.* 2004;103(8):2920-2924.
86. Kennedy GA, Seymour JF, Wolf M, et al. Treatment of patients with advanced mycosis fungoides and Sezary syndrome with alemtuzumab. *Eur J Haematol.* 2003;71(4):250-256.
87. Thursky KA, Worth LJ, Seymour JF, Prince HM, Slavin MA. Spectrum of infection, risk and recommendations for prophylaxis and screening among patients with lymphoproliferative disorders treated with alemtuzumab. *Br J Haematol.* 2006;132(1):3-12.
88. Gautschi O, Blumenthal N, Streit M, Solenthaler M, Hunziker T, Zenhausern R. Successful treatment of chemotherapy-refractory Sezary syndrome with alemtuzumab (Campath-1H). *Eur J Haematol.* 2004;72(1):61-63.
89. Kim YH, Duvic M, Obitz E, et al. Clinical efficacy of zanolimumab (HuMax-CD4): two phase 2 studies in refractory cutaneous T-cell lymphoma. *Blood.* 2007;109(11):4655-4662.
90. Whittaker SJ, Foss FM. Efficacy and tolerability of currently available therapies for the mycosis fungoides and Sezary syndrome variants of cutaneous T-cell lymphoma. *Cancer Treat Rev.* 2007;33(2):146-160.
91. Kim EJ. Immunopathogenesis and therapy of cutaneous T cell lymphoma. *J Clin Invest.* 2005;115(4):798-812.
92. Talpur R, Bassett R, Duvic M. Prevalence and treatment of *Staphylococcus aureus* colonization in patients with mycosis fungoides and Sezary syndrome. *Br J Dermatol.* 2008;159(1):105-112.
93. Duvic M, Talpur R, Wen S, Kurzrock R, David CL, Apisarnthanarax N. Phase II evaluation of gemcitabine monotherapy for cutaneous T-cell lymphoma. *Clin Lymphoma Myeloma.* 2006;7(1):51-58.
94. Marchi E, Alinari L, Tani M, et al. Gemcitabine as frontline treatment for cutaneous T-cell lymphoma: phase II study of 32 patients. *Cancer.* 2005;104(11):2437-2441.
95. Jidar K, Ingen-Housz-Oro S, Beylot-Barry M, et al. Gemcitabine treatment in cutaneous T-cell lymphoma: a multicentre study of 23 cases. *Br J Dermatol.* 2009;161:660-663.
96. Cummings FJ, Kim K, Neiman RS, et al. Phase II trial of pentostatin in refractory lymphomas and cutaneous T-cell disease. *J Clin Oncol.* 1991;9(4):565-571.
97. Dearden C, Matutes E, Catovsky D. Deoxycoformycin in the treatment of mature T-cell leukaemias. *Br J Cancer.* 1991;64(5):903-906.
98. Greiner D, Olsen EA, Petroni G. Pentostatin (2′-deoxycoformycin) in the treatment of cutaneous T-cell lymphoma. *J Am Acad Dermatol.* 1997;36(6):950-955.
99. Kurzrock R, Pilat S, Duvic M. Pentostatin therapy of T-cell lymphomas with cutaneous manifestations. *J Clin Oncol.* 1999;17(10):3117-3121.
100. Mercieca J, Matutes E, Dearden C, MacLennan K, Catovsky D. The role of pentostatin in the treatment of T-cell malignancies: analysis of response rate in 145 patients according to disease subtype. *J Clin Oncol.* 1994;12(12):2588-2593.

From bloodjournal.hematologylibrary.org by guest on May 27, 2012. For personal use only.

101. Quereux G, Marques S, Nguyen JM, et al. Prospective multicenter study of pegylated liposomal doxorubicin treatment in patients with advanced or refractory mycosis fungoides or Sezary syndrome. *Arch Dermatol.* 2008;144(6):727-733.

102. Pulini S, Rupoli S, Goteri G, et al. Pegylated liposomal doxorubicin in the treatment of primary cutaneous T-cell lymphomas. *Haematologica.* 2007; 92(5):686-689.

103. Duarte RF, Schmitz N, Servitje O, Sureda A. Haematopoietic stem cell transplantation for patients with primary cutaneous T-cell lymphoma. *Bone Marrow Transplant.* 2008;41(7):597-604.

104. Burt RK, Guitart J, Traynor A, et al. Allogeneic hematopoietic stem cell transplantation for advanced mycosis fungoides: evidence of a graft-versus-tumor effect. *Bone Marrow Transplant.* 2000;25(1):111-113.

105. Molina A, Zain J, Arber DA, et al. Durable clinical, cytogenetic, and molecular remissions after allogeneic hematopoietic cell transplantation for refractory Sezary syndrome and mycosis fungoides. *J Clin Oncol.* 2005;23(25):6163-6171.

106. Guitart J, Wickless SC, Oyama Y, et al. Long-term remission after allogeneic hematopoietic stem cell transplantation for refractory cutaneous T-cell lymphoma. *Arch Dermatol.* 2002;138(10):1359-1365.

107. Soligo D, Ibatici A, Berti E, et al. Treatment of advanced mycosis fungoides by allogeneic stem-cell transplantation with a nonmyeloablative regimen. *Bone Marrow Transplant.* 2003;31(8):663-666.

108. Herbert KE, Spencer A, Grigg A, Ryan G, McCormack C, Prince HM. Graft-versus-lymphoma effect in refractory cutaneous T-cell lymphoma after reduced-intensity HLA-matched sibling allogeneic stem cell transplantation. *Bone Marrow Transplant.* 2004;34(6):521-525.

109. Olavarria E, Child F, Woolford A, et al. T-cell depletion and autologous stem cell transplantation in the management of tumour stage mycosis fungoides with peripheral blood involvement. *Br J Haematol.* 2001;114(3):624-631.

110. Ellis L, Pan Y, Smyth GK, et al. Histone deacetylase inhibitor panobinostat induces clinical responses with associated alterations in gene expression profiles in cutaneous T-cell lymphoma. *Clin Cancer Res.* 2008;14(14):4500-4510.

111. Duvic M, Forero-Torres A, Foss F, Olsen E, Kim Y. Response to oral forodesine in refractory cutaneous T-cell lymphoma: interim results of a phase I/II study. *ASH Annual Meeting Abstracts.* 2007; 110(11):Abstract 122.

112. Zinzani PL, Musuraca G, Tani M, et al. Phase II trial of proteasome inhibitor bortezomib in patients with relapsed or refractory cutaneous T-cell lymphoma. *J Clin Oncol.* 2007;25(27):4293-4297.

113. Querfeld C, Kuzel TM, Guitart J, Rosen ST. Preliminary results of a phase II study of CC-5013 (lenalidomide, Revlimid) in patients with cutaneous T-cell lymphoma. *ASH Annual Meeting Abstracts.* 2005;106(11):Abstract 3351.

114. Weiner GJ. CpG oligodeoxynucleotide-based therapy of lymphoid malignancies. *Adv Drug Deliv Rev.* 2009;61(3):263-267.

115. Apisarnthanarax N, Talpur R, Ward S, Ni X, Kim HW, Duvic M. Tazarotene 0.1% gel for refractory mycosis fungoides lesions: an open-label pilot study. *J Am Acad Dermatol.* 2004;50(4):600-607.

116. Kreitman RJ, Wilson WH, White JD, et al. Phase I trial of recombinant immunotoxin anti-Tac(Fv)-PE38 (LMB-2) in patients with hematologic malignancies. *J Clin Oncol.* 2000;18(8):1622-1636.

117. O'Connor OA. Pralatrexate: an emerging new agent with activity in T-cell lymphomas. *Curr Opin Oncol.* 2006;18(6):591-597.

118. Diamandidou E, Colome-Grimmer M, Fayad L, Duvic M, Kurzrock R. Transformation of mycosis fungoides/Sezary syndrome: clinical characteristics and prognosis. *Blood.* 1998;92(4):1150-1159.

119. Vergier B, de Muret A, Beylot-Barry M, et al. Transformation of mycosis fungoides: clinicopathological and prognostic features of 45 cases. French Study Group of Cutaneous Lymphomas. *Blood.* 2000;95(7):2212-2218.

120. Barberio E, Thomas L, Skowron F, Balme B, Dalle S. Transformed mycosis fungoides: clinicopathological features and outcome. *Br J Dermatol.* 2007;157(2):284-289.

121. Vonderheid EC, Bernengo MG, Burg G, et al. Update on erythrodermic cutaneous T-cell lymphoma: report of the International Society for Cutaneous Lymphomas. *J Am Acad Dermatol.* 2002; 46(1):95-106.

122. Burg G, Kempf W, Cozzio A, et al. WHO/EORTC classification of cutaneous lymphomas 2005: histological and molecular aspects. *J Cutan Pathol.* 2005;32(10):647-674.

123. Diwan AH, Prieto VG, Herling M, Duvic M, Jone D. Primary Sezary syndrome commonly shows low-grade cytologic atypia and an absence of epidermotropism. *Am J Clin Pathol.* 2005;123(4): 510-515.

124. Bernengo MG, Quaglino P, Novelli M, et al. Prognostic factors in Sezary syndrome: a multivariate analysis of clinical, haematological and immunological features. *Ann Oncol.* 1998;9(8):857-863.

125. Vidulich KA, Talpur R, Bassett RL, Duvic M. Overall survival in erythrodermic cutaneous T-cell lymphoma: an analysis of prognostic factors in a cohort of patients with erythrodermic cutaneous T-cell lymphoma. *Int J Dermatol.* 2009;48(3):243-252.

126. Kim YH, Bishop K, Varghese A, Hoppe RT. Prognostic factors in erythrodermic mycosis fungoides and the Sezary syndrome. *Arch Dermatol.* 1995; 131(9):1003-1008.

127. Jackow CM, Cather JC, Hearne V, Asano AT, Musser JM, Duvic M. Association of erythrodermic cutaneous T-cell lymphoma, superantigen-positive *Staphylococcus aureus*, and oligoclonal T-cell receptor V beta gene expansion. *Blood.* 1997;89(1):32-40.

128. Oliven A, Shechter Y. Extracorporeal photopheresis: a review. *Blood Rev.* 2001;15(2):103-108.

129. Dani T, Knobler R. Extracorporeal photoimmunotherapy-photopheresis. *Front Biosci.* 2009;14: 4769-4777.

130. Scarisbrick JJ, Taylor P, Holtick U, et al. U.K. consensus statement on the use of extracorporeal photopheresis for treatment of cutaneous T-cell lymphoma and chronic graft-versus-host disease. *Br J Dermatol.* 2008;158(4):659-678.

131. Arulogun S, Prince HM, Gambell P, et al. Extracorporeal photopheresis for the treatment of Sezary syndrome using a novel treatment protocol. *J Am Acad Dermatol.* 2008;59(4):589-595.