

Superior Vena Cava Syndrome—A Proposed Classification System and Algorithm for Management

James B. Yu, MD,* Lynn D. Wilson, MD, MPH,* and Frank C. Detterbeck, MD†

Superior vena cava (SVC) syndrome has a characteristic and often striking clinical presentation, which can occasionally be life threatening. It is caused by obstruction of the SVC either by extrinsic compression or internal thrombus. Clinical signs include cyanosis, plethora, distention of subcutaneous vessels, and edema of the arms, head and neck. Edema may compromise the function of the larynx or pharynx, causing dyspnea, stridor, cough, hoarseness, and dysphagia. A more serious sequela is cerebral edema, causing headaches, confusion, and possibly coma. Cardiac output may be diminished transiently by acute SVC obstruction. However, within a few hours, the increased venous pressure forces blood through collaterals so that a steady state of blood return is once again achieved. Evidence of hemodynamic compromise is usually a result of mass effect on the heart itself rather than the SVC compression.¹⁻⁵

Traditionally, SVC syndrome has been viewed as a relative emergency. However, a recent review of data⁶ reveals that in most instances the course is relatively benign, and in fact often improves without any active treatment.⁵ Which patients require urgent intervention and which patients require little specific treatment for SVC syndrome has not been well defined. There are no detailed guidelines addressing the management of SVC obstruction. Though a general recommendation supporting the consideration of radiotherapy and/or stent placement for symptomatic SVC obstruction from lung cancer has been made both by the American College of Chest Physicians and the National Comprehensive Cancer Network, specific recommendations are currently lacking. Definition of the management is particularly important as the spectrum of possible interventions has increased, from radiotherapy and chemotherapy to thrombolytics and SVC stenting.

Definition of a nuanced approach to patients with SVC syndrome has been hampered by lack of a method to describe variations in the presentation of such patients. The purpose of

this article is to propose a classification scheme for patients with SVC obstruction according to the severity of symptoms. This in turn provides a basis for a treatment algorithm, matching different interventions with the severity of symptoms to define a rational framework of how to approach these patients.

SYMPTOMS AND PHYSIOLOGY OF SVC OBSTRUCTION

If the SVC becomes obstructed, blood flows through multiple smaller collaterals to the azygous vein or the inferior vena cava. These venous collaterals dilate over several weeks, so that the upper body venous pressure is markedly elevated initially but decreases over time.^{7,8} The severity of symptoms depends on how quickly the SVC obstruction has developed and the degree of narrowing, although acute thrombosis can also occur causing sudden exacerbation of a partial obstruction. Furthermore, the effect of SVC obstruction may be difficult to separate from the impact of compression of the heart, lungs, or airways from a large intrathoracic mass.

Elevated venous pressure causes interstitial edema of the head and neck that is visually often striking, but generally of little consequence. However, edema may narrow the lumen of the nasal passages and larynx, which can be life-threatening if severe, especially because intubation may be difficult to perform. Cerebral edema can also occur and can lead to cerebral ischemia, herniation, and death because the skull creates a closed compartment. Elevation of the head is usually of little benefit if venous collaterals have not yet dilated enough and hyperventilation may be problematic because of difficulties with intubation. Cardiac output may be diminished transiently by acute SVC obstruction, but within a few hours a steady state of blood return is achieved by the increased venous pressure and collaterals. Hemodynamic compromise is usually a result of mass effect on the heart rather than the SVC compression.⁶

Signs and symptoms of SVC obstruction however, are usually more of a nuisance than of clinical consequence. In a review of 1986 cases of SVC obstruction, only one documented case of death was found, in this case from epistaxis.⁹ Two additional deaths resulted from rupture of an aortic aneurysm that was causing SVC syndrome. Only anecdotal cases of neurologic or laryngeal compromise were identified, and in these it was unclear whether the symptoms were caused by other factors (brain metastases or tracheal com-

*Yale Thoracic Oncology Program, Yale Cancer Center and the Department of Therapeutic Radiology, †Yale Thoracic Oncology Program, Yale Cancer Center and the Division of Thoracic Surgery, Department of Surgery, Yale University, New Haven, Connecticut.

Disclosure: The authors declare no conflicts of interest.

Address for correspondence: Frank Detterbeck, MD, Yale University, 330 Cedar Street, New Haven, CT 06520-8062. E-mail: frank.detterbeck@yale.edu

Copyright © 2008 by the International Association for the Study of Lung Cancer

ISSN: 1556-0864/08/0308-0811

pression).^{9,10} Furthermore, in animal studies acute ligation of the SVC above the azygous vein resulted in listless behavior that resolved with 1 week in all cases.¹¹

CLINICAL EVALUATION

Patient evaluation should begin with a history and physical examination with attention to the duration of symptoms, a history of previous invasive procedures, and a history of malignancy. The diagnosis of SVC syndrome is made clinically on the basis of signs and symptoms, as listed in Table 1. In most cases symptoms are generally progressive over several weeks and then get better over time.⁶ Further investigation must be performed to look for related additional problems as these are common in patients with malignant SVC syndrome. These can include the presence of brain metastases, major compression of the tracheobronchial tree, or of the heart from mass effect. These additional issues may cause symptoms by themselves that may be mistakenly attributed to SVC obstruction if a thoughtful and careful history and examination is not done.

PROPOSED CLASSIFICATION SYSTEM

The severity of symptoms is important in determining the urgency of intervention. This has not been well characterized in existing studies because of the lack of a classification scheme. A proposed scheme is shown in Table 2. Use of this schema in future studies should provide a common language to describe the patients and thereby help define the role of interventions. This schema is patterned after the Common Terminology Criteria for Adverse Events (CTCAE) v3.0 of the National Institutes of Health and divided into mild, moderate, severe, life threatening, and fatal symptoms. However, it should be emphasized that grade 3, 4, or 5 symptoms are quite rare. The CTCAE does not address SVC syndrome, although it does include a category of edema of the head and neck. The grading in this CTCAE category is similar to the proposed schema, except that the CTCAE is more narrowly focused whereas the proposed schema includes all symptoms caused by SVC obstruction.

Because the severity of symptoms of SVC syndrome change over time, the time point at which the symptoms are graded must be included in future studies using the proposed classification system. For example, important time points might be at the time of presentation, at the time of initiation of treatment, or after the treatment has been finished. Assessment of the efficacy of a treatment could be measured by a change in symptom severity from just before treatment to after completion of treatment. Ideally one would have a comparison group who did not get the treatment, otherwise it is difficult to evaluate the effect of the treatment versus the simple passage of time.

An important feature of the proposed grading system is the differentiation between severe, life-threatening, and non-life threatening situations. Severe symptoms are classified as including mild or moderate cerebral edema causing headache and dizziness, mild or moderate laryngeal edema, or diminished cardiac reserve manifesting as syncope after bending. Life threatening symptoms include significant

TABLE 1. Symptoms and Signs Associated with Superior Vena Cava Syndrome

Sign or Symptom	Percentage of All Patients	Reported Range (%)
Hemodynamic		
Facial edema	82	60–100
Arm edema	46	14–75
Distended neck veins	63	27–86
Distended chest veins	53	38–67
Facial plethora	20	13–23
Visual symptoms	2	—
Respiratory		
Dyspnea	54	23–74
Cough	54	38–70
Hoarseness	17	—
Stridor	4	—
Neurologic		
Syncope	10	8–13
Headaches	9	6–11
Dizziness	6	2–10
Confusion	4	—
Obtundation/CVA	2	—

Data from Refs. 1, 4, 5, 21, 22, 23.

CVA, cerebral vascular accident (stroke).

cerebral edema causing confusion and obtundation, significant laryngeal edema causing stridor and potential airway compromise, significant hemodynamic compromise causing syncope without precipitating factors, hypotension, or renal insufficiency.

TREATMENT ALGORITHM FOR MALIGNANT CAUSES

In the case of a malignancy causing SVC obstruction, management issues include treatment of the malignancy itself and treatment aimed at relief of the symptoms of SVC obstruction. A median life expectancy of about 6 months has been noted in patients with malignant SVC obstruction.^{4,5,12,13} However, there are numerous reports of patients achieving long-term (>5 years) survival after treatment of malignant SVC obstruction,¹² and the survival of patients presenting with SVC obstruction does not seem to be different from that of patients with the same tumor type and stage without SVC obstruction.^{3,9,14,15} Thus, it appears clear that the presence of malignant SVC obstruction does not alter the need to treat the underlying malignancy as dictated by the type and stage of tumor.

Management of the SVC obstruction itself is dictated by the severity of the symptoms, the likelihood of response to a particular treatment, and the treatment of the malignancy itself. Thus, the right approach will be influenced by the symptoms, the type and stage of malignancy, the patient's performance status, and comorbidities. Traditional medical treatment such as corticosteroids and diuretics are not supported by data demonstrating benefit.⁶

When symptoms are life threatening (grade 4), immediate intervention is indicated and should be directed at

TABLE 2. Proposed Grading System for Superior Vena Cava Syndrome

Grade	Category	Estimated Incidence (%)	Definition ^a
0	Asymptomatic	10	Radiographic superior vena cava obstruction in the absence of symptoms
1	Mild	25	Edema in head or neck (vascular distention), cyanosis, plethora
2	Moderate	50	Edema in head or neck with functional impairment (mild dysphagia, cough, mild or moderate impairment of head, jaw or eyelid movements, visual disturbances caused by ocular edema)
3	Severe	10	Mild or moderate cerebral edema (headache, dizziness) or mild/moderate laryngeal edema or diminished cardiac reserve (syncope after bending)
4	Life-threatening	5	Significant cerebral edema (confusion, obtundation) or significant laryngeal edema (stridor) or significant hemodynamic compromise (syncope without precipitating factors, hypotension, renal insufficiency)
5	Fatal	<1	Death

^a Each sign or symptom must be thought due to superior vena cava obstruction and the effects of cerebral or laryngeal edema or effects on cardiac function. Symptoms caused by other factors (e.g., vocal cord paralysis, compromise of the tracheobronchial tree, or heart as a result of mass effect) should not be considered as they are due to mass effect on other organs and not superior vena cava obstruction.

urgent relief of the SVC obstruction (Figure 1). Intravascular stenting is safe and provides the most immediate relief.⁶ An intervention to relieve the obstruction can be done before obtaining a tissue diagnosis.⁶ Stenting can often be accomplished even if there is complete SVC obstruction or thrombosis, particularly if thrombolytics are first used.⁶

An argument can be made to extend the recommendation for stenting to patients with grade 3 symptoms; however, this is probably best reserved for those patients unable to tolerate optimal treatment of their underlying malignancy or patients with persistent symptoms after treatment. This rec-

ommendation is based on the need for treatment of the underlying malignancy, the generally good response rates (even with time alone), and the cost of stenting.

If symptoms are not life threatening, the ultimate outcome and survival from SVC syndrome is dependent on the underlying root cause. Therefore, patients with grade 1 and 2 and most with grade 3 symptoms should undergo diagnostic and staging procedures to define the tumor type and stage. The data clearly shows that this can be accomplished safely in experienced hands despite SVC obstruction.⁶ A stage- and tumor-specific treatment plan should be

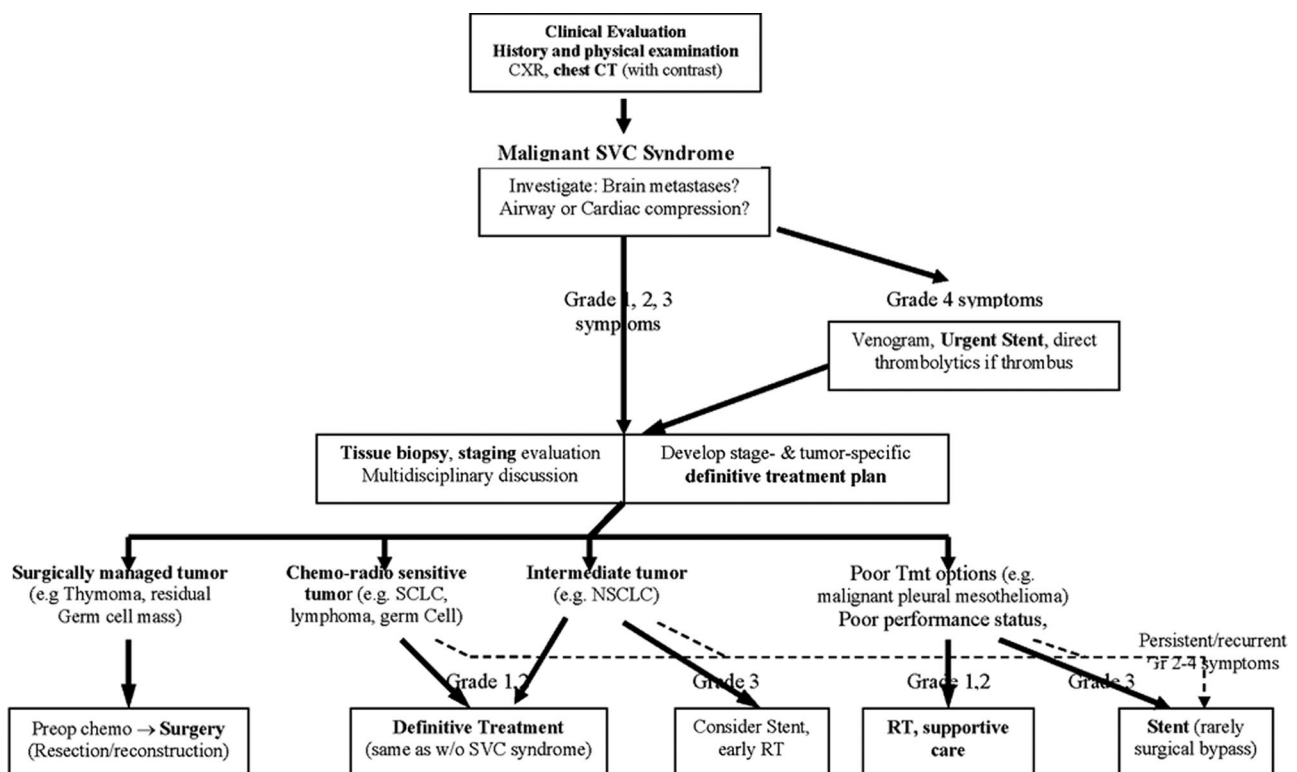


FIGURE 1. Proposed management algorithm.

developed (typically the same treatment as for patients without caval obstruction).

Patients with lymphoma, small-cell lung cancer, and germ cell tumors should experience a rapid clinical response from systemic chemotherapy. Stenting is of questionable value in such patients. The majority of patients with non-small-cell lung cancer experience relief of obstructive symptoms with definitive treatment (chemotherapy for stage IV, chemoradiotherapy for stage III), but the rate of response is less than that seen in more chemo and radiosensitive tumors.⁶ Stent placement in such patients with grade 3 symptoms may be reasonable. Stenting should be strongly considered in patients with tumors for which effective treatment approaches are very limited (e.g., mesothelioma). Patients with thymoma and caval obstruction should undergo chemotherapy followed by resection,¹⁶ and stenting should be avoided because it complicates resection.

The benefit of anticoagulation is unclear, although thrombolytics are useful if there is caval thrombosis.^{12,17,18} Anticoagulation after thrombolysis and consideration of the use of aspirin after stent placement alone has been recommended by several authors.^{12,17}

Whether a brain metastasis should affect the management of SVC syndrome is unclear. Stenting for such patients has been considered because of the potential of increased cerebral edema, but at least temporary anticoagulation is needed and cerebral hemorrhage has been documented. For those with both SVC syndrome and airway obstruction, optimal management approaches are uncertain. Some suggest resection (either complete or subtotal) to establish immediate and simultaneous relief of the clinical problems.^{19,20} The treatment of relapsed SVC obstruction is unclear. Stenting should be considered because the response to additional chemotherapy or radiation may be limited or technically not possible.

CONCLUSION

In conclusion, we have proposed a grading system based on clinical findings for SVC syndrome from malignant causes. We hope this grading system will facilitate communication and allow collation and comparison of results from different institutions. We have proposed an algorithm for the treatment of SVC syndrome based the presence or absence of potential life-threatening symptoms, performance status of the patient, and the histology of the tumor (Figure 1). Both the grading system and the management algorithm need validation and further refinement. However, we hope they provide a starting point that allows an evidence-based approach to develop.

REFERENCES

1. Armstrong BA, Perez CA, Simpson JR, Hederman MA. Role of irradiation in the management of superior vena cava syndrome. *Int J Radiat Oncol Biol Phys* 1987;13:531–539.
2. Abner A. Approach to the patient who presents with superior vena cava obstruction. *Chest* 1993;103:394S–397S.
3. Ostler PJ, Clarke DP, Watkinson AF, Gaze MN. Superior vena cava obstruction: a modern management strategy. *Clin Oncol* 1997;9:83–89.
4. Yellin A, Rosen A, Reichert N, Lieberman Y. Superior vena cava syndrome: the myth—the facts. *Am Rev Respir Dis* 1990;141:1114–1118.
5. Schraufnagel DE, Hill R, Leech JA, Pare JAP. Superior vena caval obstruction: is it a medical emergency? *Am J Med* 1981;70:1169–1174.
6. Wilson LD, Detterbeck FC, Yahalom J. Clinical practice. Superior vena cava syndrome with malignant causes. *N Engl J Med* 2007;356:1862–1869.
7. Kim HJ, Kim HS, Chung SH. CT diagnosis of superior vena cava syndrome: importance of collateral vessels. *AJR Am J Roentgenol* 1993;161:539–542.
8. Trigaux JP, van Beers B. Thoracic collateral venous channels: normal and pathologic CT findings. *J Comput Assist Tomogr* 1990;14:769–773.
9. Ahmann FR. A reassessment of the clinical implications of the superior vena cava syndrome. *J Clin Oncol* 1984;2:961–969.
10. Kishi K, Sonomura T, Mitsuzane K, et al. Self-expandable metallic stent therapy for superior vena cava syndrome: clinical observations. *Radiology* 1993;189:531–535.
11. Carlson HA. Obstruction of the superior vena cava—an experimental study. *Arch Surg* 1934;29:669–677.
12. Marcy PY, Magne N, Bentolila F, Drouillard J, Bruneton JN, Descamps B. Superior vena cava obstruction: is stenting necessary? *Support Care Cancer* 2001;9:103–107.
13. Greiller L, Barlesi F, Doddoli C, et al. Vascular stenting for palliation of superior vena cava obstruction in non-small cell lung cancer patients: a future ‘standard’ procedure? *Respiration* 2004;71:178–183.
14. Sculier JP, Evans WK, Feld R, et al. Superior vena caval obstruction syndrome in small cell lung cancer. *Cancer* 1986;57:847–851.
15. Magnan PE, Thomas P, Guidicelli R, Fuentes P, Brancherau A. Surgical reconstruction of the superior vena cava. *Cardiovasc Surg* 1994;2:598–604.
16. Detterbeck FC, Parsons AM. Thymic tumors. *Ann Thorac Surg* 2004;77:1860–1869.
17. Nicholson AA, Ettles DF, Arnold A, et al. Treatment of malignant superior vena cava obstruction: metal stents or radiation therapy. *J Vasc Interv Radiol* 1997;8:781–788.
18. Uberoi R. Cirsé guidelines: quality assurance guidelines for superior vena cava stenting in malignant disease. *Cardiovasc Intervent Radiol* 2006;29:319–322.
19. Inoue M, Minami M, Shiono H, et al. Efficient clinical application of percutaneous cardiopulmonary support for perioperative management of huge anterior mediastinal tumor. *J Thorac Cardiovasc Surg* 2006;131:755–756.
20. Takeda SI, Miyoshi S, Omori KI, Okumura M, Matsuda H. Surgical rescue for life-threatening hypoxemia caused by a mediastinal tumor. *Ann Thorac Surg* 1999;68:2324–2326.
21. Chen JC, Bongard F, Klein SR. A contemporary perspective on superior vena cava syndrome. *Am J Surg* 1990;160:207–211.
22. Rice TW, Rodriguez RM, Barnette R, Light RW. Prevalence and characteristics of pleural effusions in superior vena cava syndrome. *Respirology* 2006;11:299–305.
23. Urruticoechea A, Mesia R, Dominguez J, et al. Treatment of malignant superior vena cava syndrome by endovascular stent insertion Experience on 52 patients with lung cancer. 2004;43:209–214.